

Case Report

Open Access

A Novel Technique for Calcaneal Avulsion Fracture: A Case Report

Shingo Shimozaki^{1,2*}, Hiroyuki Inatani^{1,2}, Hitoaki Numata² and Hiroyuki Tsuchiya²

¹Department of Orthopedic Surgery, Fujii Neurosurgical Hospital, Japan

²Department of Orthopedic Surgery, Graduate School of Medical Sciences, Kanazawa University, Japan

*Corresponding author: Shingo Shimozaki, Department of Orthopedic Surgery, Graduate School of Medical Sciences, Kanazawa University, Japan, Tel: +81762645111; E-mail: spbc8h69@gaea.ocn.ne.jp

Rec date: Sep 27, 2016; Acc date: Oct 26, 2016; Pub date: Oct 28, 2016

Copyright: © 2016 Shimozaki S, et al. This is an open-access article distributed under the terms of the creative commons attribution license, which permits unrestricted use, distribution, and reproduction in any medium, provided the original author and source are credited.

Abstract

Avulsion fractures of the calcaneal tuberosity constitute only a small percentage of calcaneal fractures. Avulsion fractures often occur in elderly women with osteoporosis. Various surgical methods are used in the treatment of this type of fracture. These include tension band wiring, suture anchor fixation, lag screw fixation, and TightRope® technique. In order to manage these fractures effectively, it is important to avoid skin necrosis and to ensure strong fixation that can resist the pull of triceps surae. We performed a novel technique using Achilles SpeedBridge™ and a cannulated lag screw. This technique allows for strong and easy fixation. A 57-year-old man presented to our department with a left ankle injury caused by slipping on a rocky area next to the sea. We diagnosed a type I calcaneal avulsion fracture, and planned surgical fixation. Surgery was performed 3 days after the injury. Postoperatively, the patient used a brace to maintain the ankle in the natural position for three weeks. Full weight bearing was started with Achilles boots after the brace was removed. His ankle range of motion was 30° plantar flexion and 60° dorsiflexion. He could perform all movements without any issues and without requiring support. His preoperative American Orthopaedic Foot and Ankle Society score was 52/100, and after 3 months this had increased to 100/100. We believe that this technique is highly effective for the treatment of type I calcaneal avulsion fractures.

Keywords: Calcaneus; Achilles tendon; Avulsion fracture; Knotless anchor; Lag screw

Introduction

Only a small percentage of calcaneus fractures occur on the calcaneal tuberosity [1-3]. Beavis et al classified these fractures into three types. A type I fracture is a true avulsion type, called a “sleeve” fracture; a type II fracture is an “open beak” type; and a type III fracture is a type of infrabursal avulsion of the middle third of the tuberosity [3]. Recently, Lee et al. modified the classification to include four types [4]. In this classification, the type I, II, and III fractures are the same as the previous classification. A type IV fracture retains continuity of the Achilles tendon superficial fibers, but not the deep fibers, on magnetic resonance imaging. The type I fracture is the most common calcaneal avulsion fracture (40%). Early surgical treatment is recommended with this type of fracture to ensure correct reduction and avoid skin complications. Reports have outlined the surgical treatment techniques for this type of fracture, including tension band wiring [5], lag screws with washers [6], suture anchors [7-10], and the TightRope® technique [11]. During surgery for calcaneal avulsion fractures, it is important to avoid skin and soft tissue complications and to ensure strong fixation to resist the pull of triceps surae. We present a novel technique of fixing a displaced calcaneal avulsion fracture using the Achilles SpeedBridge™ (Arthrex) with a lag screw. This new device had been developed as a novel concept in Achilles reattachment, following debridement of the Haglund prominence. We used this device to perform strong fixation for a calcaneal avulsion fracture.

Case Report

A 57-year-old man presented to our department with a left ankle injury caused by slipping on rocky area next to the sea. We diagnosed a calcaneal avulsion fracture using plain radiography and computed tomography. The patient underwent 3 days of elevating, resting and cooling the injury (Figure 1). Because the skin condition was acceptable for surgical treatment, we performed an open reduction and internal fixation.

Surgical exploration and fixation were carried out with the patient under lumbar anesthesia. A direct midline incision was made posteriorly with the patient in the prone position. The incision was continued down to the middle third of the calcaneal tuberosity to expose the calcaneus fracture. The investing fascia was incised to expose the Achilles tendon and the avulsed bone fragment. We observed some small fragments at the site of the fracture, which were not attached to the Achilles tendon.

Debridement of the fracture site was performed, and these fragments were removed, except for a large fragment attached to the Achilles tendon. We then used the new device, the Achilles SpeedBridge™, to perform fixation of the avulsion fracture with a lag screw (Figure 2). We inserted the two 4.75 mm BioComposite SwiveLock® proximal anchors into the proximal calcaneal fracture surface after preparing the holes with the provided drill. Because this type of fracture often occurs in elderly women with osteoporosis, we recommend inserting the proximal anchor into cortical bone, rather than just cancellous bone.

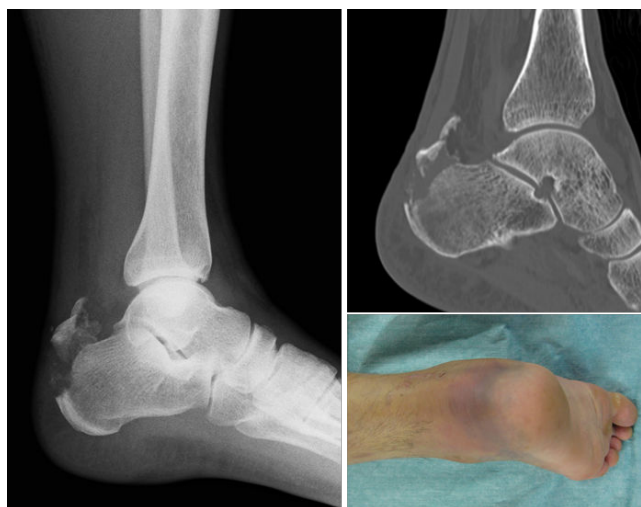

Figure 1: A plain radiograph (left hand panel) and computed tomography image (upper right) demonstrating a type I calcaneal avulsion fracture. The skin condition was acceptable at the time of surgery (lower right), 3 days after the trauma.

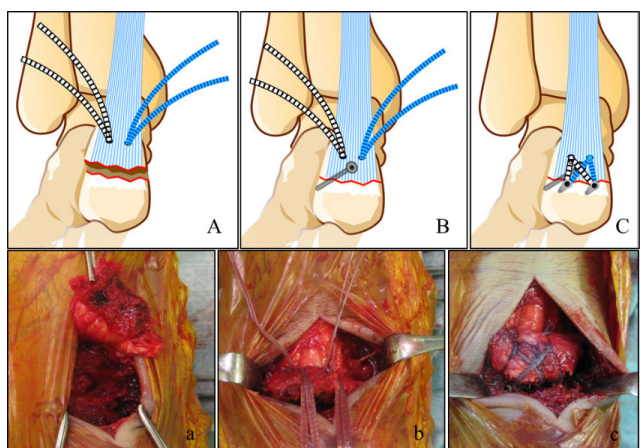


Figure 2: The surgical technique for calcaneal avulsion fracture using the Achilles SpeedBridge™: (A, a) insert proximal anchors and pass the FiberTape® through the Achilles tendon; (B, b) reduce the fragment attached to the Achilles tendon and stabilize it using the lag screw; (C, c) insert distal anchors and cut the tails of the FiberTape®.

The proximal anchors were loaded with the FiberTape®. We passed the needle attached to the FiberTape® through the Achilles tendon, and pulled down the Achilles tendon with the attached fragment for reduction. Because the fragment attached to Achilles tendon was large enough, we inserted a 4.0 mm cannulated lag screw into it to strengthen the fixation. Then, we prepared the distal holes using the drill provided in the same manner as the proximal holes. We retrieved one FiberTape® tail from each proximal anchor, adjusted the tension of the FiberTape®, and inserted the BioComposite SwiveLock® C distal anchors into the prepared distal holes. Finally, we cut the tails flush to

the distal anchor, resulting in the final knotless repair (Figure 3). We sutured the paratenon and skin without any tension.

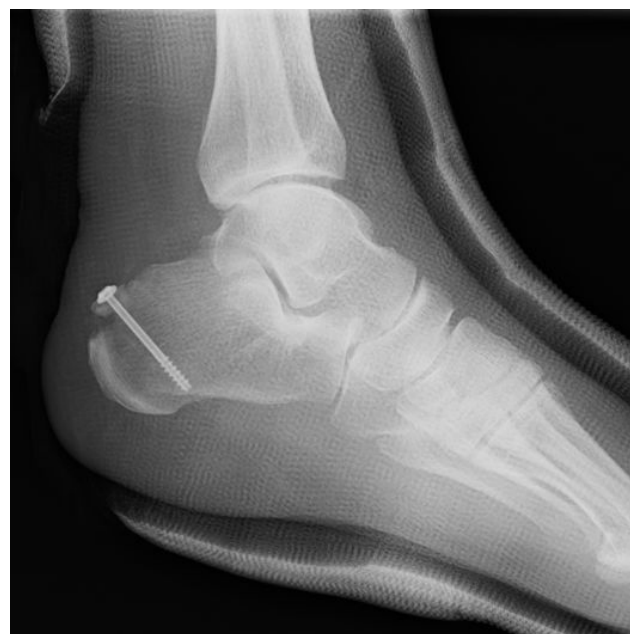

Figure 3: Post-operative plain radiograph.

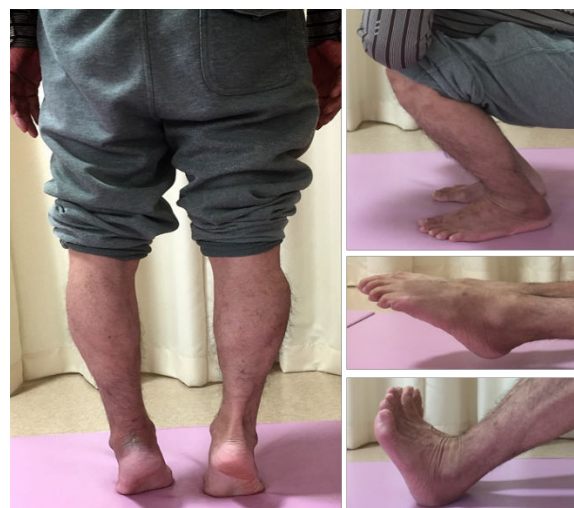

Figure 4: The patient could stand on his toes (left hand panel) and crouch (upper right). His ankle range of motion was excellent, in both plantar flexion (middle right) and dorsiflexion (lower right).

Postoperatively, the patient used a brace to maintain the ankle in the natural position (20° plantar flexion) for three weeks. Full weight bearing with Achilles boots and range of movement exercise were started after the brace was removed. The follow-up period was 12 months. At 3 months, his ankle range of motion was 60° plantar flexion and 30° dorsiflexion (Figure 4), and he could perform all movements without any difficulty of support. His preoperative American orthopaedic foot and ankle society score was 52/100, and after 3

months, it had increased to 100/100. At 1 year, postoperative, the patient had gained normal ankle ROM with clinically full-strength triceps surae muscle function (Figure 5).

Discussion

Calcaneal avulsion fractures are infrequent, and are diagnosed by radiography. Open reduction and internal fixation is recommended to achieve good fixation and to retain the function of triceps surae. In order to manage this fracture effectively, it is important to avoid skin necrosis and to ensure strong fixation that can resist the pull of triceps surae. There are some reports regarding the surgical management of this type of fracture. Tension band wiring allows good fixation, but sometimes cause skin and soft tissue problems due to the edge of the wire [5].

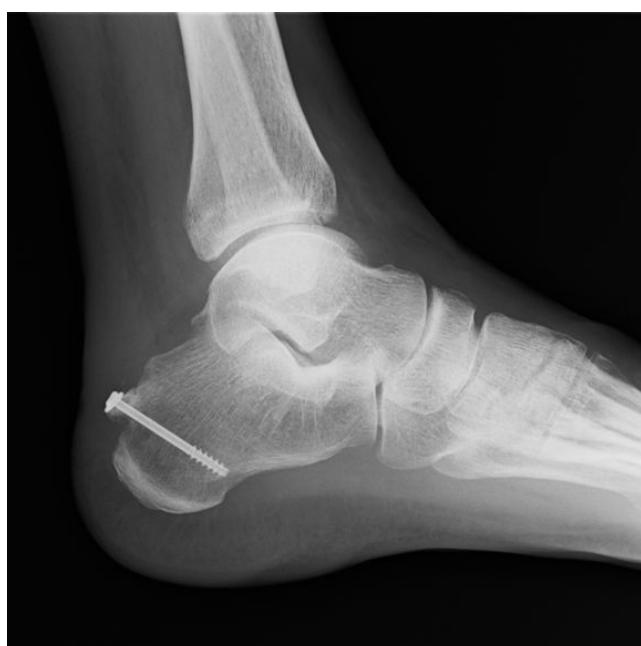

Figure 5: Plain radiograph after two months.

Lag screw fixation is also effective for bone healing because it is a compression technique, but it needs a large fragment attached to Achilles tendon to allow the insertion of at least two screws with washers [6]. Suture anchor and TightRope® techniques achieve good results [7-11], but they require suturing of the normal Achilles tendon 3 cm to 4 cm proximal to the entheses. Khazen et al. reported that suture anchor augmentation significantly improved the strength of screw fixation in posterior calcaneal tuberosity avulsion fractures [12]. Therefore, we performed fixation using the Achilles SpeedBridge™ and a lag screw, and achieved an excellent result. This technique allows for strong and easy fixation. In addition, it can be used for small fragment avulsion fractures without a knot of fiber wire. The important feature

of this technique is that a lag screw must be inserted before the distal anchors. If you insert the distal anchors before the lag screw, you cannot ensure high tension in the Achilles SpeedBridge™. We removed the small fragments unattached to the Achilles tendon to debulk the subcutaneous space, and because they would have become painful mice. Because this type of fracture often occurs in elderly woman with osteoporosis, it is the important to insert the screw into the cortical bone to resist the strong pull of triceps surae.

In conclusion, we have described a novel method of repairing the calcaneal avulsion fractures using a strong, easy, and reliable technique. It can be used for small fragment avulsion fractures. We believe that this technique is highly effective for the treatment of type I calcaneal avulsion fractures.

Acknowledgements

We thank Masanori Suzuki (Fujii Neurosurgical Hospital), physical therapist, for assistance in the postoperative rehabilitation.

References

1. Cooper DE, Heckman JD (1989) The heel of Achilles: calcaneal avulsion fracture from a gunshot wound. *Foot Ankle* 9: 204-206.
2. Rockwood CA, Green DP, Bucholz RW, Heckman JD, Court-Brown CM (2006) *Rockwood and Green's Fractures in Adults*, (Eds.) Lippincott Williams & Wilkins, Philadelphia, .
3. Beavis RC, Rourke K, Court-Brown B (2008) Avulsion fracture of the calcaneal tuberosity: A case report and literature review. *Foot Ankle Int* 29: 863-866.
4. Lee SM, Huh SW, Chung JW, Kim DW, Kim YJ, et al. (2012) Avulsion fracture of the calcaneal tuberosity: classification and its characteristics. *Clin Orthop Surg* 4: 134-138.
5. Nagura I, Fujioka H, Kurosaka M, Mori H, Mitani M, et al. (2012) Modified tension band wiring fixation for avulsion fractures of the calcaneus in osteoporotic bone: A review of three patients. *J Foot Ankle Surg* 51: 330-333.
6. Rijal L, Sagar G, Adhikari D, Joshi KN (2012) Calcaneal tuberosity avulsion fracture: an unusual variant. *J Foot Ankle Surg* 51: 666-668.
7. Lui TH (2009) Fixation of tendo Achilles avulsion fracture. *Foot Ankle Surg* 15: 58-61.
8. Greenhagen RM, Highlander PD, Burns PR (2012) Double row anchor fixation: A novel technique for a diabetic calcaneal insufficiency avulsion fracture. *J Foot Ankle Surg* 51: 123-127.
9. Zhao BX, Wang KZ, Wang CS, Xie Y, Dai ZT, et al. (2011) Treatment of calcaneal avulsion fractures with twinfix suture anchors fixation. *Zhongguo Gu Shang* 24: 527-528.
10. Hasegawa N, Nakamura T, Maruhashi Y, Matsumoto N, Hagiwara N, et al. (2014) Treatment of calcaneal avulsion fractures with suture anchors fixation: three cases report. *Journal of Japanese Society for Fracture Repair* 36: 406-409.
11. Hard Z, Dacheppalli S, Mani G (2013) An alternative method of fixation of calcaneal tuberosity fractures using the Tightrope(®) technique. *J Foot Ankle Surg* 52: 762-764.
12. Khazen GE, Wilsion AN, Ashfaq S, Parks BG, Schon LC (2007) Fixation of calcaneal avulsion fractures using screws with and without suture anchors: a biomechanical investigation. *Foot Ankle Int* 28: 1183-1186.