

# A New Case of Primary Signet Ring Cell Carcinoma of the Uterine Cervix: A Case Report and Review of the Literature

Doghri R<sup>1</sup>, Tounsi N<sup>2\*</sup>, Slimane M<sup>2</sup>, Boujelbene N<sup>1</sup>, Driss M<sup>1</sup>, Charfi L<sup>1</sup>, Rahal K<sup>2</sup> and Mrad K<sup>1</sup>

<sup>1</sup>Department of Pathology, Salah-Azaiez Institute, Boulevard, Tunis, Tunisia

<sup>2</sup>Department of Surgery Carcinologique, Salah-Azaiez Institute, Boulevard, Tunis, Tunisia

## Abstract

Primary signet-ring cell carcinoma of cervix is extremely rare in the literature. Usually Signet-Ring Cell Carcinomas (SRCCs) of the cervix are metastatic from a primary gastric, colonic, ovarian, or breast carcinoma. A 48-year-old woman was referred to our Department due to persistent abnormal vaginal bleeding during the last two months. Gynecologic examination revealed cervical tumor. Biopsy revealed a signet ring cell type of mucinous adenocarcinoma. Extensive systemic examination reveals liver metastases biopsies confirmed. The patient was treated with palliative chemotherapy. The prognosis of primary signet ring cell adenocarcinoma of the uterine cervix is still unclear because of the rare incidence of cases. In this report we reviewed the literature to identify the clinical, pathological and immunohistochemical features of this rare malignancy.

**Keywords:** Cervix neoplasms; Signet ring cell carcinoma; Immunohistochemical; Adenocarcinoma

## Introduction

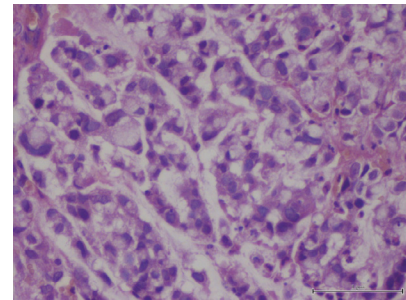
Carcinoma of the uterine cervix is the most common malignancy in female genital tract in developing countries [1]. The current frequency of cervical adenocarcinoma is 10% to 25% of all the cervical carcinomas in developed countries and most of them are endocervical type [1].

Mucinous adenocarcinoma of the cervix was subdivided into 5 subtypes: endocervical, intestinal, signet-ring cell, minimal deviation, and villoglandular [2]. Adenocarcinomas with signet ring cell are mostly metastatic from gastric, breast, colonic or ovarian carcinomas and primary tumor is extremely rare [1-3]. The prognosis of primary signet-ring cell carcinoma (PSRCCs) of the cervix is not well known as a result of the small number of case reports.

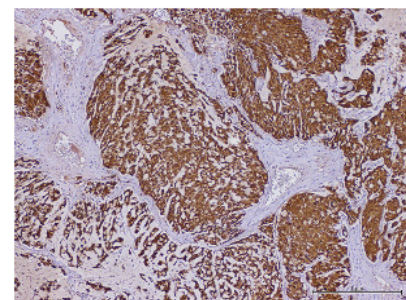
We describe a case of primary adenocarcinoma of the uterine cervix, signet-cell type. In addition, we reviewed all reported cases in the literature, to the best of our knowledge.

## Case Report

A 48-year-old woman, gravida seven, para five, aborta 2, married at the age of 18 not yet menopause and her medical and family history was unremarkable. She was a heavy smoker (two pack/day) for 10 years, no alcohol, and used oral contraceptives on and off for about 10 years. She was admitted to our hospital for spontaneous and intermittent abnormal vaginal bleeding which had been present during the last two months. Gynecological examination revealed diffuse enlargement of the cervix which had been replaced by an exophytic ulcerated, reddish lesion with distal parametrial infiltration. We performed a cervical biopsy and endocervical curettage. Microscopic examination shows cells with eccentric hyperchromatic nuclei and large mucin filled cytoplasmic vacuoles growing in clusters and in nests or columns within pools of extracellular mucin (signet-ring cells) (Figures 1-3). An extensive immunohistochemical evaluation of the biopsies was performed. The neoplastic cells were diffusely positive for p16, Cytokeratin 7 and carcinoembryonic antigen, whereas cytokeratin 20, chromogranin A, synaptophysin, vimentin and hormonal (estrogens and progesterone) receptors were negative. Abdominal pelvic magnetic resonance imaging (MRI) demonstrated about 53 mm × 36 mm size mass in the endocervical canal. Chest X-ray, gastroscopy, colonoscopy



**Figure 1:** Microscopic examination shows cells with eccentric hyperchromatic nuclei and large mucin filled cytoplasmic vacuoles growing in clusters and in nests or columns within pools of extracellular mucin (signet-ring cells) (×400).



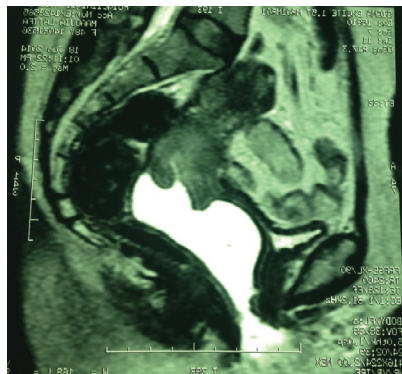
**Figure 2:** Immunohistochemical analysis showed positivity to p16 (× 200).

\*Corresponding author: Tounsi N, Department of Surgery Carcinologique, Salah-Azaiez Institute, Boulevard of 9-Avril, 1001 Tunis, Tunisia, Tel:71563980; E-mail: [Neserine.tounsi@gmail.com](mailto:Neserine.tounsi@gmail.com)

Received August 24, 2017; Accepted October 11, 2017; Published October 16, 2017

**Citation:** Doghri R, Tounsi N, Slimane M, Boujelbene N, Driss M, et al. (2017) A New Case of Primary Signet Ring Cell Carcinoma of the Uterine Cervix: A Case Report and Review of the Literature. J Cancer Sci Ther 9: 713-716. doi:10.4172/1948-5956.1000496

**Copyright:** © 2017 Doghri R, et al. This is an open-access article distributed under the terms of the Creative Commons Attribution License, which permits unrestricted use, distribution, and reproduction in any medium, provided the original author and source are credited.



**Figure 3:** Abdominopelvic magnetic resonance imaging (MRI): the tumor measured 53 mm × 36 mm size in the endocervical canal. Induration extended to the parametria.

total, oral endoscopy and mammography, failed to show any other primary tumor. We practiced an abdominal pelvic scanner which revealed lombo-aortic adenopathy as well as hepatic metastasis biopsy-confirmed. All these results were consistent with a primary PSRCC FIGO (2009) cervical tumor stage IVB. The patient was referred to medical oncology for palliative treatment. Cisplatin has been indicated at doses 50 mg/m<sup>2</sup> once every 3 weeks. But, his health condition had severely and rapidly deteriorated, therefore she doesn't receive chemotherapy. She was deceased three months later.

### Discussion

The most common adenocarcinoma of the uterine cervix is the usual endocervical type [1]. Mucinous adenocarcinoma of signet-ring cell type is very rare [4,5]. Usually, signet-ring cell differentiation found in cervical carcinoma strongly suggests a metastatic carcinoma usually from a gastro-intestinal, appendicular, mammary or ovarian origin

Authors, years	Age (yrs)	Presenting symptoms	FIGO stage	Immunohistochemical studies other than ER and PR	ER, PR	HPV	Treatment	Outcome
Moll et al. [9]	50	Post-coital vaginal bleeding, menometrorrhagia	III	NA	NA	NA	Sx ,RT	DOD 10 mo
Mayorga et al. [6]		Post-coital bleeding	Ib	NA	NA	NA	Pre-chemo, Sx	NED 35 Mo
case (1)	68							
case (2)	74	Post-menopausal bleeding	Ib	NA	NA	NA	Sx	NED 25 Mo
Haswani et al. [5]		Post-coital vaginal bleeding In both cases	III	NA	ER: -	HPV type 18: +	Palliative RT and chemo	DOD 10 mo
case (1)	33							
case (2)	38		Ib	NA	ER: -, R: -	NA	Sx and RT	NED 18 Mo
Cardosi et al. [10]	53	Perimenopausal bleeding	Ib	NA	ER+ PR +	NA	Sx RT Chemo	NED 6 Mo
Moritani et al. [14]	29	Persistent abnormal genital Bleeding	III	Positive for CK, MUC5AC Negative for vimentin, MUC2, MUC6	ER: -, PR: -	-	Chemo	NED 6 Mo
Insabato et al. [8]	46	Vaginal bleeding in cervical polypoid lesion	Ib	NA	NA	NA	Sx,RT,Chemo	NED 8 Yrs
Suárez et al. [7]	80	Vaginal discharge	IIIB	Positive for CK AE1-AE3, CK 20, CEA, chromogranin A, synaptophysin Negative for vimentin, S-100 protein, HMB-45, adrenocorticotrophic hormone, prolactin, thyroid-stimulating hormone, follicle-stimulating hormone, luteinizing hormone, growth hormone, GCDFFP 15	NA	NA	Rx Chemo	DOD 18 Mo
Mc Cluggage et al. [17]	NA	Two cases NA	NA	Positive for CK 7 and CK 16	NA	NA	NA	NA
(2 cases)				Negative for CK 20 and CDX2				
Versas et al. [13]		Thromboembolic events (Trousseau Syndrome)	IV	Positive for p16 and CK 7 Negative for CK 20, CDX2 and Dpc4.	ER: -, PR: -	+	Chemo	DOD 7 wks
(2009) [3]	36							
Case (2)	43	Metastases of lung and lymph nodes	IV	positive for p16 and CK negative for CK 20, CDX2 and mammaglobin			Chemo	DOD 2
Lowery et al. [15]	60	Post-menopausal bleeding	Ib1	NA	NA	NA	RT brachytherapy Sx	DOD>10 years
Balci et al. [2]	53	Post-menopausal bleeding	IIB	Positive for CK, p16, CEA, MUC1, and MUC5. Negative for CK 20, GCDFFP 15, MUC2, chromogranine, synaptophysin, PGP 9.5, CD56, vimentin, CDX-2, TTF-1, and mammaglobin	ER: -, PR: -	HPV type 18: +	Sx	NR

Yoon et al (2011) [1]	47	post-coital bleeding	Ib	Positive for p53 and Rb	NA	NA	Sx	NED 6 mo
Giordano et al. [4]	45	Vaginal discharge	IIB	Positive for CK 7, CA-125, CEA and p16 Negative for vimentin,	NA	HPV type 18: +	Sx	NA
O. Kaidar-Person [16]	37	post-coital bleeding	IIB2	Negative for chromogranin , synaptosin, CEA.	NA	NA	concomitant chemo radiotherapy brachytherapy Sx	NED 4 mo
Washimi et al. [11]	31	Abnormal vaginal bleeding.	Ila	Positive for MUC2, CDX2, CEA, CK7. Negative for MUC1, MUC5AC, MUC6, p53, CK20, TTF-1, GCDFFP-1, mammoglobin, chromogranin-1, p16, HIK1083.	ER: -, PR: -	HPV type 18: +	Sx and chemo	Disease-free at 41 mo
Cracchiolo et al. [12]	64	Abdominal fullness.	IVB	Cytokeratin 7, (CEA) P16 positive (GCDFFP), S-100 protein synaptophysin, (SMA) CDX-2, colon carcinoma and Cytokeratin 20 negative.	ER: +, PR: +	-	Palliative	± 3 mo
Sal et al. [13]	48	Postcoital vaginal bleeding	Ib	Positivity for p16, CDX-2, MUC1, MUC2 and MUC5AC. Negativity for synaptophysin, chromogranin A and CK-20	ER: -, PR: -	HPV type 18: +	Sx	Disease-free at 18 mo

CKCK: Cytokeratin; MUC: Mucin; TTF: Thyroid Transcription Factor; GCDFFP: Gross Cystic Disease Fluid Protein; ER: Estrogen Receptor; PR: Progesterone Receptor; NA: Not Available; Sx: Surgery; Rx: Radiation Therapy; DOD: Died of Disease; NED: Not Evidence of Disease; Mo: Months; Yrs: Years; Wks: Weeks; Chemo: Chemotherapy; CEA: Carcinoembryonic Antigen; CDX-2: Caudal-Type Homeobox 2; SMA: Smooth Muscle Actin; PGP: Protein Gene Product; TTF: Thyroid Transcription Factor 1; Pre-Chemo: Preoperative Chemotherapy

**Table 1:** Previous reported cases of primary cervical carcinoma containing signet-ring cell morphology.

[1,6]. To the best of our knowledge, only 20 cases (included our case) of primary cervical carcinoma containing signet-ring cell morphology have been reported in the literature (Table 1). In most cases of previous reports, the signet-ring cell component is included in a part of histological types [6]. All cases were admitted as primary only after a careful combined clinical, endoscopic and radiological investigation to rule out the presence of an occult primary site. Immunohistochemical and molecular studies have often provided important information for differential diagnosis. Several immunohistochemical markers have been used in the literature to support the primary origin of cervical cancer, although their usefulness is debatable. Indeed, primary cervical carcinoma can express colorectal antigens such as ACE, caudal-related homeoboxn (CDX-2) and cytokeratin 20 (CK20) [7,8]. Moreover, simultaneous positivity to ACE and keratin 7 do not differentiate between PCSRCC and gastric or mammary metastatic malignancy [5]. However, positivity for mammoglobin favors a mammary origin. No positive case of PCSRCC was reported [5]. Oestrogen and progesterone receptors have been tested in only 4 previous cases [2,3,9] and these were present only in one example [10]. Neuroendocrine differentiations have been demonstrated in two cases [7,10] but these markers were negative in our case. Positivity of Human Papillomavirus (HPV) DNA using molecular analysis provides diagnostic evidence of primary signet- ring cell carcinoma of the cervix [4,5]. The presence of HPV 18 has been determined in five cases of primary signet-ring cell carcinoma of the cervix [4,7,11-13]. No case was reported with negative p16 immunohistochemical staining [13]. In our case, as well as in some previous published examples of the PCSRCC, the primary cervical origin was supported by the presence of P16 Immunoreactivity [12,13], which may be considered a surrogate marker for HPV infection [4]. The absence of extra genital pathology, demonstrated by investigations at the moment of the diagnosis and later in the course of the disease, also supports this opinion [7]. The prognosis of primary signet-ring cell carcinoma of the cervix is not well known [1]. Ten patients had localized disease to the cervix and eight patients had advanced tumors

[2,4,5,7,10-14], in one cases with stage IV, was expired shortly after 3 months [12]. However, extended survival in a low-stage tumor was reported in two cases [8,15]. We have not a clear consensus; the treatment of this rare tumor joins the treatment recommendations for uterine cervix adenocarcinoma [16]. A resistance to radiotherapy and/or chemotherapy was reported [3-5,7,9]. But it has been suggested that advanced stage disease is particularly aggressive [4,7,12,14].

## Conclusion

Primary signet-ring cell carcinomas of the cervix are rare and associated with a poor outcome [17]. Prognosis seems to be related to the clinical stage [4,10]. Awareness of this entity is important as it simulate metastatic signet-ring cell carcinoma. Clinical investigations and immunohistological studies are essentials for differential diagnosis [4,8].

## Competing Interests

The authors declare that they have no competing interests.

## Ethical Approval

Our study did not require ethical form.

## Consent

Written informed consent form was obtained from the patient for publication of this case report and images.

## References

1. Yoon A, Kim SH, Kim HJ, Bae DS, Lee JW (2011) Primary signet ring cell carcinoma of the uterine cervix: A case report. *KJOG* 54: 570-573.
2. Balci S, Saglam A, Usulutun A (2010) Primary signet-ring cell carcinoma of the cervix: Case report and review of the literature. *Int J Gynecol Pathol* 29: 181-184
3. Veras E, Srodon M, Neijstrom ES, Ronnett BM. (2009) Metastatic HPV-related cervical adenocarcinomas presenting with thromboembolic events (Trousseau Syndrome): clinicopathologic characteristics of 2 cases. *Int J Gynecol Pathol* 28: 134-139.

4. Giordano G, Pizzi S, Berretta R, D'Adda T (2012) A new case of primary signet-ring cell carcinoma of the cervix with prominent endometrial and myometrial involvement: Immunohistochemical and molecular study and review of the literature. *World J Surg Oncol* 11: 10.
5. Haswani P, Arseneau J, Ferenczy A (1998) Primary signet ring cell carcinoma of the uterine cervix: A clinicopathologic study of two cases with review of the literature. *Int J Gynecol Cancer* 8: 374-379.
6. Mayorga M, Garcia-Valtuille A, Fernandez F, Val-Bernal JF, Cabrera E (1997) Adenocarcinoma of the uterine cervix with massive signet-ring cell differentiation. *Int J Surg Pathol* 5: 95-100.
7. Suárez-Peñaranda JM, Abdulkader I, Barón-Duarte FJ, González Patiño E, Novo-Domínguez A, et al. (2007) Signet-ring cell carcinoma presenting in the uterine cervix: Report of primary and 2 metastatic cases. *Int J Gynecol Pathol* 26: 254-258.
8. Insabato L, Simonetti S, De Cecio R, Di Tuoro S, Bifulco G, et al. (2009) Primary signet-ring cell carcinoma of the uterine cervix with long term follow-up: case report. *Eur J Gynaecol Oncol* 28: 411-414.
9. Moll UM, Chumas JC, Mann WJ, Patsner B (1990) Primary signet ring cell carcinoma of the uterine cervix. *N Y State J Med* 90: 559-560.
10. Cardosi RJ, Reedy MB, Van Nagell JR, Spires SE (1990) Neuroendocrine signet ring cell adenocarcinoma of the endocervix. *Int J Gynecol Cancer* 9: 433-437.
11. Washimi K, Okose T, Noguchi A, Ono K, Kawachi K, et al. (2015) Diagnosis of primary pure signet-ring cell carcinoma of the cervix. *Pathol Int* 65: 393-395.
12. Cracchiolo B, Kuhn T, Heller D (2015) Primary signet ring cell adenocarcinoma of the uterine cervix- A rare neoplasm that raises the question of metastasis to the cervix. *Gynecol Oncol Rep* 16: 9-10.
13. Sal V, Kahramanoglu I, Turan H, Tokgozoglu N, Bese T, et al. (2016) Primary signet ring cell carcinoma of the cervix: A case report and review of the literature. *Int J Surg Case Rep* 21: 1-5.
14. Moritani S, Ichihara S, Kushima R, Sugiura F, Mushika M, et al. (2004) Combined signet ring cell and glassy cell carcinoma of the uterine cervix arising in a young Japanese woman: A case report with immunohistochemical and histochemical analyses. *Pathol Int* 54: 787-792.
15. Lowery WJ, Difurio MJ, Sundborg MJ, Leath CA (2011) Cervical signet-ring cell carcinoma presenting as a synchronous primary carcinoma with uterine adenocarcinoma. *Mil Med* 174: 212-213.
16. Kaidar-Person O, Amit A, Berniger A, Ben-Yosef R, Kuten A, et al. (2013) Primary signet-ring cell adenocarcinoma of the uterine cervix: Case report and review of the literature. *Eur J Gynaecol Oncol* 34:353.
17. Mc Cluggage WG, Shah R, Connolly LE, Mc Bride HA (2008) Intestinal-type cervical adenocarcinoma *in situ* and adenocarcinoma exhibit a partial enteric immunophenotype with consistent expression of CDX2. *Int J Gynecol Pathol* 27: 92-100.