

A Fat Embolism Case with Fat Globules on Retinal Examination

Eyüp Sabri Uçan¹, Ali Osman Saatçi², Onur Turan^{1*}, Önder Limon³ and Tuba Gümüş⁴

¹Dokuz Eylül University The Faculty Of Medicine; Chest Diseases Department, Turkey

²Dokuz Eylül University The Faculty Of Medicine; Ophthalmology Department, Turkey

³Dokuz Eylül University The Faculty Of Medicine; Emergency Department, Turkey

⁴Yesilyurt State Hospital, Internal Medicine Department, Turkey

*Corresponding author: Onur Turan, Dokuz Eylül University, Faculty of Medicine, Department of Chest Diseases, Izmir, Turkey, Tel: 90-0232-239-19-70; E-mail: onurtura@yahoo.com

Received date: Jul 04, 2014, Accepted date: Aug 28, 2014, Published date: Sep 01, 2014

Copyright: © 2014 Turan O, et al. This is an open-access article distributed under the terms of the Creative Commons Attribution License, which permits unrestricted use, distribution, and reproduction in any medium, provided the original author and source are credited.

Abstract

Fat embolism, which is an important type of non-thrombotic embolism, is generally seen as a complication of long bone trauma. It presents with respiratory, circulatory, neurological system symptoms. This multisystemic diseases may end with mortality. A 27-year-old man referred to our hospital with confusion, dyspnea and fever. His complaints started after a long leg cast applied because of a right tibia fracture 36 hours ago. Chest radiograph showed bilateral reticulonodular densities His arterial blood gases measurement revealed hypoxemia and hypocapnia. There was no pulmonary embolism shown in thorax CT angiography, as demonstrating bilateral diffuse infiltrations. Fat embolism was thought in differential diagnosis with a clinical presentation of acute respiratory disease syndrome (ARDS). The ophthalmologists found out characteristic fat globules on retinal examination. Intravenous glucocorticoid, oxygen and supportive treatment were administered for the patient. Clinical improvement was observed during follow-up, as his symptoms and radiological findings regressed. Our case revealed respiratory insufficiency (one major criteria), high fever, retinal signs, oliguria and tachycardia (four minor criteria), and high sedimentation rate (one laboratory finding), which met the criteria for FES. We want to present our fat embolism case with characteristic properties of this rarely seen disease with characteristic fat globules on retinal examination.

Keywords: Acute respiratory disease syndrome; Fat embolism; Long bone trauma; Retinal fat globules; Supportive treatment

Introduction

Fat embolism is a syndrome commonly associated with orthopedic injuries, such as long bone fractures. It is a rare complication that occurs in 0.5 to 2% of patients following this kind of fractures [1] typically after 24 to 72 hours. It is believed to be caused by the toxic effects of fat globules coming from disrupted tissues. Fat embolism may affect multiorgan systems including the lungs, brain, skin, eyes, and heart [2]. It may be life threatening as mortality seems from 5 to 15 percent [3], and clinical manifestation may progress to severe hypoxemia and acute respiratory disease syndrome (ARDS) requiring mechanical ventilation [4].

Fat embolism syndrome (FES) is a clinical diagnosis based on respiratory, cerebral and dermal manifestations. Different clinical presentations may occur in this disease according to affected organs by fat globules.

We present a case of fat embolism with tibia fracture who developed severe respiratory failure and had retinal fat globules, which is characteristic for this disease.

Case Report

A 27-year-old man referred to our hospital with confusion, dyspnea and fever. It was learnt that a long leg cast had been applied because of a right tibia fracture 36 hours ago, and his complaints started in this period. No important detail was noticed about patient's medical

history. He developed a fever of 39.5°C, with tachypnea and tachycardia (130 beats/min). The cooperation and orientation of the patient were poor. The neurological examination and cranial CT were normal. Lung auscultation revealed decrease of breathing sounds and crackles in all areas of the lung.

Pulmonary embolism was considered as the diagnosis, so arterial blood gas, routine biochemical and hemogram parameters, D-dimer level and a chest radiograph were obtained. The patient had hypoxemia and hypocapnia in arterial blood gases measurement; pH: 7.47, PCO₂: 26.1 mmHg and PO₂: 53.4 mmHg with 90.2% saturation. Serial arterial blood gas measurements revealed persistent hypoxemia. His hemogram showed leucocytosis with WBC count of 12.200/UL, without thrombocytopenia and anemia. His sedimentation rate was reported as 42 mm/h. His chest radiograph showed bilateral reticulonodular densities (Figure 1a). D-dimer level was 285.6 ug/L (<or= 500 ug/L: normal). There was no pulmonary embolism shown in thorax CT angiography, as demonstrating bilateral diffuse infiltrations.

Fat embolism was thought in differential diagnosis of the patient having a clinical presentation of acute respiratory disease syndrome (ARDS). There was neither jaundice nor petechial rash in the physical exam. The output of urine was calculated as 300 ml/day; no fat globules in urine were found.

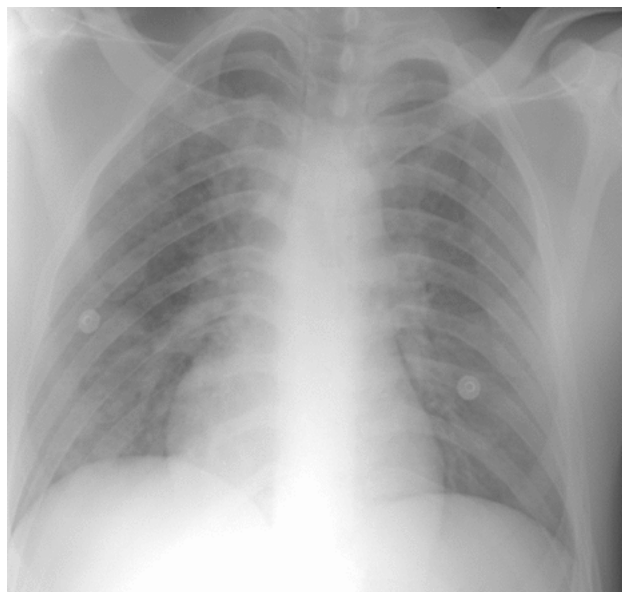


Figure 1a: Initial chest radiograph with bilateral diffuse infiltrations

Ophthalmologists were consulted to look for retinal globules. As they found out characteristic fat globules on retinal examination (Figures 2a and b), the patient was diagnosed as fat embolism. Intravenous glucocorticoid, oxygen and supportive treatment were administered after diagnosis. Clinical improvement was observed during follow-up. Pulmonary symptoms resolved in a few hours; also radiological findings regressed in a short time (Figure 1b). ABG analysis revealed no more hypoxemia. The general health status of the patient made a good progress; and he was discharged from hospital with the plan of reducing glucocorticoid dosage in stages.

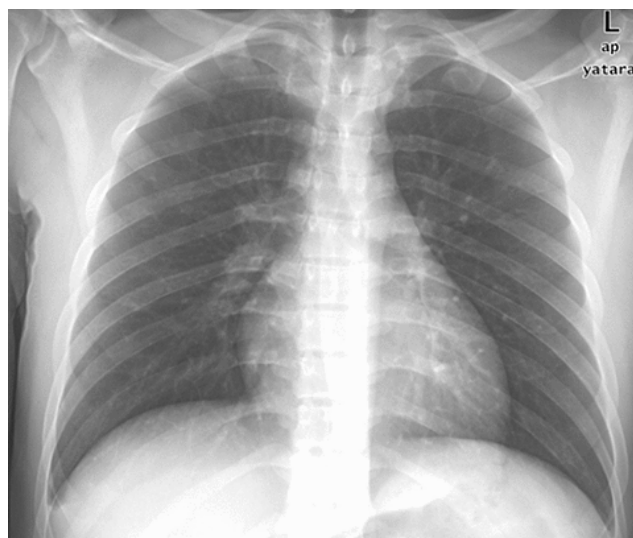

Figure 1 b: Control chest radiograph after treatment

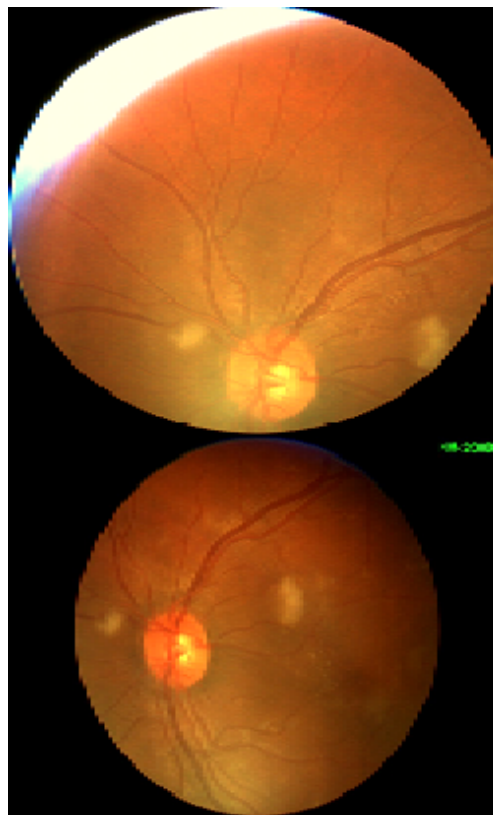


Figure 2 a-b: Characteristic fat globules on retinal examination

Discussion

Fat embolism is a syndrome associated with the release of free fatty acids into systemic circulation after a traumatic event, mostly associated with long bone and pelvic fractures [5]. Lipoprotein lipase hydrolyzes triglycerides to free fatty acids and glycerol, which releases some substances toxic for the capillary endothelium [6]. The obstruction of the capillaries of end organs activates the inflammatory cascade and damages lung parenchyma, producing alveolar hemorrhage and edema [7]. Affected patients usually present with a classic triad: pulmonary distress, changes in mental status, and petechial rash [8]. Fat embolism typically occurs 24 to 72 hours after the inciting event.

The most frequent early symptoms in fat embolism are dyspnea and tachypnea; nearly half of patients develop severe hypoxemia and require mechanical ventilation with ARDS [4]. The chest radiograph generally reveals diffuse bilateral infiltrates and opacities. Neurological abnormalities may develop in the majority of patients after the development of respiratory distress, from focal abnormalities to diffuse encephalopathy, with mostly seen presentations such as unconsciousness and seizures [9]. Petechiae, the last component of the triad to develop, may also be seen in fat embolism in 50–60% of cases with representing dermal fat embolization [10].

Some minor manifestations of fat embolism may also be present, such as lipiduria, retinal changes, fever and coagulation abnormalities due to the release of toxic mediators [11].

Fat embolism retinopathy is an important manifestation in FES. Retinal findings generally include cotton-wool spots and intraretinal hemorrhages. Although 5% of patients with long bone fractures had also retinal findings, they occur in 50–60% in patients who meet the diagnostic criteria for FES [10]. Retinal microinfarcts from fatty emboli, which have been demonstrated histopathologically, may explain the presence of retinal findings [12].

Gurd et al. and some other articles suggested some criteria including some major and minor symptoms and laboratory findings for diagnosis of fat embolism [10]. As many diseases may be thought in the differential diagnosis of fat embolism, the disease is generally diagnosed by clinical properties with nonspecific laboratory and radiographic findings, which seems to be an exclusion diagnosis [13]. Our case revealed respiratory insufficiency (one major criteria), high fever, retinal signs, oliguria and tachycardia (four minor criteria), and high sedimentation rate (one laboratory finding), which met the criteria for FES.

There is no specific drug therapy for fat embolism; supportive care is generally recommended [14]. Supportive care includes cardiovascular and respiratory resuscitation and stabilization. Intravascular volume replacement and administration of oxygen are known as other useful treatment components. The role of glucocorticoids in the treatment of fat embolism is still controversial. It is said to be used to decrease brain edema, lung inflammation and capillary endothelial damage [15]. Some studies indicate that the development of fat embolism may decrease by using glucocorticoid prophylaxis in patients with long bone fractures [16]. There are no controlled clinical trials demonstrating efficacy of this therapy.

As a conclusion, we would like to take attention to fat embolism which should be considered in a clinical presentation of acute respiratory disease syndrome (ARDS) that occurs after a long bone fracture (Table 1).

Major criteria	Petechial rash
(one necessary for diagnosis)	Respiratory insufficiency
	Cerebral involvement
Minor criteria	Tachycardia >120 beats•min ⁻¹
(four necessary for diagnosis)	Fever >39.4°C
	Retinal signs – fat or petechiae
	Jaundice
	Renal signs – anuria or oliguria

Laboratory findings	Thrombocytopenia
(one necessary for diagnosis)	Anemia
	High erythrocyte sedimentation rate
	Fat macroglobulinemia

Table 1: Gurd's criteria for diagnosis of FES

FES=fat embolism syndrome.

References

- Saigal R, Mittal M, Kansal A, Singh Y, Kolar PR, et al. (2008) Fat embolism syndrome. *J Assoc Physicians India* 56: 245-249.
- Taviloglu K, Yanar H (2007) Fat embolism syndrome. *Surg Today* 37: 5-8.
- Mellor A, Soni N (2001) Fat embolism. *Anaesthesia* 56: 145-154.
- King MB, Harmon KR (1994) Unusual forms of pulmonary embolism. *Clin Chest Med* 15: 561-580.
- Syed MI, Jan S, Patel NA, Shaikh A, Marsh RA, et al. (2006) Fatal fat embolism after vertebroplasty: identification of the high-risk patient. *AJNR Am J Neuroradiol* 27: 343-345.
- Nakata Y, Tanaka H, Kuwagata Y, Yoshioka T, Sugimoto H (1999) Triolein-induced pulmonary embolization and increased microvascular permeability in isolated perfused rat lungs. *J Trauma* 47: 111-119.
- Parisi DM, Koval K, Egol K (2002) Fat embolism syndrome. *Am J Orthop (Belle Mead NJ)* 31: 507-512.
- Carr JB, Hansen ST (1990) Fulminant fat embolism. *Orthopedics* 13: 258-261.
- Byrick RJ (2001) [Fat embolism and postoperative coagulopathy]. *Can J Anaesth* 48: 618-621.
- Gurd AR, Wilson RI (1974) The fat embolism syndrome. *J Bone Joint Surg Br* 56B: 408-416.
- Weinhouse (2009) Fat embolism syndrome. UpToDate Inc.
- KEARNS TP (1956) Fat embolism of the retina demonstrated by a flat retinal preparation. *Am J Ophthalmol* 41: 1-2.
- Christie J, Robinson CM, Pell AC, McBirnie J, Burnett R (1995) Transcardiac echocardiography during invasive intramedullary procedures. *J Bone Joint Surg Br* 77: 450-455.
- Jenkins K, Chung F, Wennberg R, Etchells EE, Davey R (2002) Fat embolism syndrome and elective knee arthroplasty. *Can J Anaesth* 49: 19-24.
- Levy D (1990) The fat embolism syndrome. A review. *Clin Orthop Relat Res* : 281-286.
- Kallenbach J, Lewis M, Zaltzman M, Feldman C, Orford A, et al. (1987) 'Low-dose' corticosteroid prophylaxis against fat embolism. *J Trauma* 27: 1173-1176.