

Case Report

Open Access

A Change of Statin Leading to Severe Rhabdomyolysis and Acute Kidney Injury

Adam Czapran*, Krishna Appunu and Indranil Dasgupta

Department of Renal medicine, Heartlands Hospital, United Kingdom

Case Presentation

In December 2010, a 43 year old South Asian woman presented to the acute medical unit with a 7 day history of coryzal symptoms, a non-productive cough and 5 days of leg weakness and muscular aches. She presented due to the worsening of symptoms and confusion. She also noted that she was passing less urine than usual.

She had a background of iron deficiency anaemia, type II diabetes mellitus and uterine fibroids. She had also previously, a cholecystectomy. Her regular medications included aspirin, Humalog mix 50 biphasic insulin twice daily, norethisterone, ferrous sulphate, danazol, vildagliptin/metformin, and simvastatin 40 mg daily. She was put on ibuprofen and tramadol 4 days before for her aches and pain.

On examination her observations were within normal limits, but she demonstrated tenderness to palpation in the lower back, thighs and calves. She was anuric. Her blood tests showed a new onset Acute Kidney Injury (AKI), her previous renal function being normal. Her urea was 18.6 mmol/L and her creatinine was 633 $\mu\text{mol/L}$ with an estimated Glomerular Filtration Rate (eGFR) of 6 ml/min/1.73 m^2 . Her TSH was not raised. The provisional diagnosis was AKI secondary to recent non-steroidal usage and pyelonephritis. She was treated with intravenous fluid and antibiotics. She remained anuric and was referred to the renal team. Further blood tests revealed a Creatine Kinase (CK) of 94,820 U/L. This prompted further questioning into her drug history. It transpired that she had previously been on atorvastatin 20 milligrams nightly for several years, but that her general practitioner changed this to simvastatin 40 milligrams nightly two weeks prior to admission. She was subsequently treated as AKI secondary to statin induced rhabdomyolysis. She achieved full renal recovery following 23 sessions of intermittent haemodialysis via a tunnelled line. Dialysis was discontinued at day 36 post admission (Figure 1).

The authors appreciate there are some other possible causes of this lady's acute kidney and rhabdomyolysis other than being induced by a change in statin. This patient was taking Danazol and norethisterone, which is also metabolized by CYP3A4, an enzyme which metabolizes atorvastatin and simvastatin [1]. Subsequently, co-administration may have increased the likelihood of rhabdomyolysis. The authors also appreciate that this patient's rhabdomyolysis may not have been statin

induced, as a result of over exertion or from a viral cause, although the patient had not been undertaking any more physical activity than usual. Additionally, her renal dysfunction was likely to have been further exacerbated by her concurrent use of non-steroidal anti-inflammatory drugs. Although there are possibilities for other mechanisms for this patient's acute kidney injury and rhabdomyolysis, it is most likely that her condition was induced by the changing of atorvastatin to simvastatin and the associated increase in dose.

The association between statin use and rhabdomyolysis is well documented [2]. The risk of rhabdomyolysis is known to increase in older patients and in those with type II diabetes mellitus [3]. This risk is also increased when statins are co-administered with other drugs such as amiodarone, ciclosporin, fibrates and macrolide antibiotics [4]. This case is unusual in that rhabdomyolysis was induced by changing from atorvastatin to simvastatin, in addition to a dose increase, leading to catastrophic consequences; she developed severe AKI necessitating prolonged hospital admission and multiple sessions of intermittent haemodialysis before her kidney function recovered. This occurred even though had been long established on atorvastatin, danazol and norethisterone. Therefore, such patients should be monitored more closely both clinically and biochemically when changing between statins or changing doses. It should also be noted that some statins have a higher potential to cause rhabdomyolysis (i.e. simvastatin) than other HMGCoA reductase inhibitors (i.e. fluvastatin or atorvastatin) and that changing to a different agent may increase the risk of developing this condition [5].

Learning Points for Clinicians

This case is relevant to primary care practitioners, emergency department doctors and acute physicians because the presenting symptoms of acute rhabdomyolysis are non-specific. The clinician needs to be aware of the potential for precipitating severe rhabdomyolysis when changing statin especially to a higher dose and also need to take account of concomitant usage of other medication that can either cause muscle damage or potentiate the effect of a statin. This occurred in this patient's case, even though she was already established on a statin.

Contributors

Adam Czapran wrote the first draft and is corresponding author; Krishna Appunu and Indranil Dasgupta were involved with clinical

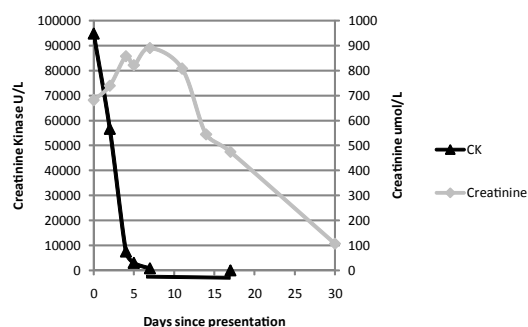


Figure 1: A graph plotting time since the patient's presentation against her creatine kinase level (left y-axis) and serum creatinine level (right y-axis). Haemo dialysis took place on days 1, 2, 3, 4, 5, 7, 8, 9, 10, 11, 14, 15, 16, 17, and on three times a week basis thereafter until day 36 post admission.

*Corresponding author: Dr. Adam Czapran, Heartlands Hospital, Bordesley Green East, Birmingham B9 5SS, United Kingdom, Tel: +44-1214242158; Fax: +44-1214241159; E-mail: adamczapran@nhs.net

Received March 07, 2013; Accepted April 01, 2013; Published April 03, 2013

Citation: Czapran A, Appunu K, Dasgupta I (2013) A Change of Statin Leading to Severe Rhabdomyolysis and Acute Kidney Injury. J Clin Case Rep 3: 266. doi:10.4172/2165-7920.1000266

Copyright: © 2013 Czapran A, et al. This is an open-access article distributed under the terms of the Creative Commons Attribution License, which permits unrestricted use, distribution, and reproduction in any medium, provided the original author and source are credited.

care of this patient and contributed to further drafts of the article. ID is the guarantor. Adam Czapran is the corresponding author.

References

1. Lee CA, Neul D, Clouser-Roche A, Dalvie D, Wester MR, et al. (2010) Identification of novel substrates for human cytochrome P450 2J2. *Drug Metab Dispos* 38: 347-356.
2. Dormuth CR, Hemmelgarn BR, Paterson JM, James MT, Teare GF, et al. (2013) Use of high potency statins and rates of admission for acute kidney injury: multicenter, retrospective observational analysis of administrative databases. *BMJ* 346: f880.
3. Hansen KE, Hildebrand JP, Ferguson EE, Stein JH (2005) Outcomes in 45 patients with statin-associated myopathy. *Arch Intern Med* 165: 2671-2676.
4. Abd TT, Jacobson TA (2011) Statin-induced myopathy: a review and update. *Expert Opin Drug Saf* 10: 373-387.
5. Rallidis LS, Fountoulaki K, Anastasiou-Nana M (2012) Managing the underestimated risk of statin-associated myopathy. *Int J Cardiol* 159: 169-176.