

Case Report

Open Access

# A Case Report of Long-Term Survival Cancer Patient after Right Lung was Resected and Left Lung Late Course Shrinking GTV and Boost Radiotherapy

Zhan-zhao Fu and Shao-hui Cheng\*

Department of oncology, The First Hospital of Qinhuangdao, Heibei Province, China

## Abstract

Three-dimensional conformal radiotherapy (3D-CRT) can improve local control of non-small cell lung cancer [1]. During the period of radiotherapy, tumor appears different degrees of shrinkage. It has been demonstrated that a clear dose-response relationship exists for radiotherapy, i.e. higher doses of radiation lead to increased local tumor control. According to tumor regression degree, adjusting the field shape and radiation strength, improve the tumor tissue irradiation dose, decrease peripheral normal tissue affected by radiation, improve local tumor control and prolong the survival time.

## Introduction

It was reported a special case of a locally advanced squamous cell carcinoma of the left lung. Due to pulmonary tuberculosis, the patient had undergone a complete right-side pulmonary lobectomy twenty years ago. Left lungs supports his life, he is unable to carry on an operation treatment, so he accepted radiotherapy. Firstly, we defined gross tumor volume (GTV1) by CT simulation location, 3D-CRT was used until tumor dose reached 50 Gy/25f. Secondly, by repeating the planning CT scan, defined GTV2, continued to radiotherapy by 2.5 Gy/f until the dose was 65 Gy/31f. Using the same method for third CT scan, defined GTV3, continued to radiotherapy by 3 Gy/f until the total dose was 74 Gy/34f. After radiotherapy, the patient acquired complete response and he had no obvious side-effect of radiotherapy. There has been no recurrence for 5 years now.

## Case Report

The patient is a 46 years old middle aged man. 20 years ago, he took pulmonary tuberculosis and underwent a complete right-side pulmonary lobectomy. Because of cough and expectoration with blood, in June 2007, he took a chest CT scan and found that there was a lump showed on his left lung (Figure 1). Further checked by fibrous bronchus mirror, pathology diagnosis was poorly differentiated squamous cell carcinoma. After the complete right-side pulmonary lobectomy, the patient can't take left lung pulmonary lobectomy any more due to his right side of thorax collapse. So 3D-CRT was adopted.

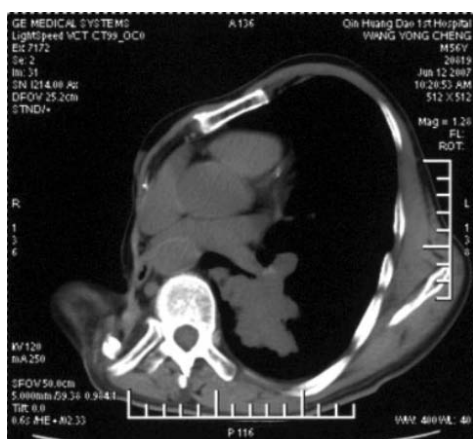


Figure 1: Chest CT scan showed lump on left lung.

First CT fixed position scan, input TPS planning system, outlined GTV1, made an proposal 1 (Figure 2), Using 4 ~ 6 fixed field or non coplanar field, with 90% to 95% isodose curve covering PTV1, PRIMUS H 6MV-X type linear accelerator manufactured by German company SIEMENS was implemented into treatment. DT 180 cGy / times, 1 times / day, 5 times / week. After three-dimensional conformal radiotherapy 4500 cGy/25f, 2nd round fixed position scan was taken, outlined GTV2, defined shrinking, made proposal 2 (Figure 3), a single dose increased to 200 cGy, / continued radiotherapy of the DT 6500 cGy. The therapeutic effect is a Complete Response (CR) after radiotherapy (Figure 4), traced until Feb. 2011, there are no radiation

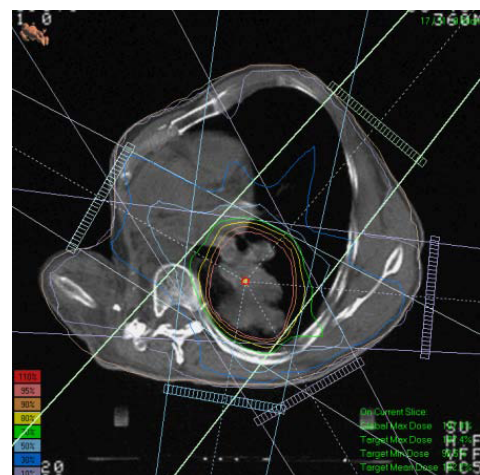


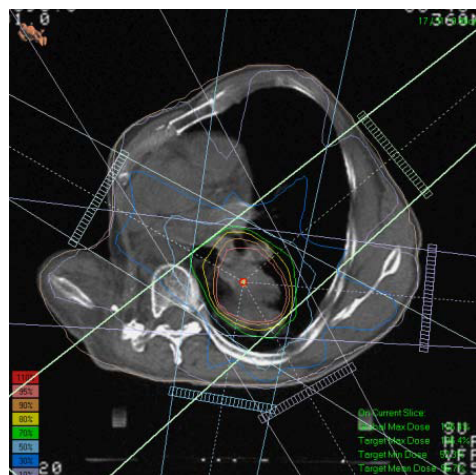
Figure 2: First CT fixed position scan, input TPS planning system, outlined GTV1, made proposal 1.

\*Corresponding author: Shao-hui Cheng, Department of oncology, The first hospital of Qinhuangdao, Heibei province, China, E-mail: [rechal\\_ch@aol.com](mailto:rechal_ch@aol.com)

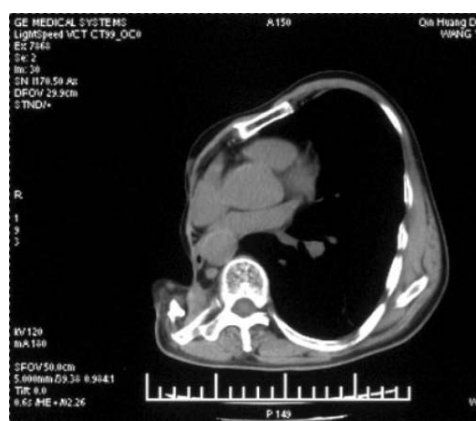
Received April 25, 2012; Accepted June 16, 2012; Published June 26, 2012

Citation: Fu Z, Cheng S (2012) A Case Report of Long-Term Survival Cancer Patient after Right Lung was Resected and Left Lung Late Course Shrinking GTV and Boost Radiotherapy. J Clin Case Rep 2:158. doi:10.4172/2165-7920.1000158

Copyright: © 2012 Fu Z, et al. This is an open-access article distributed under the terms of the Creative Commons Attribution License, which permits unrestricted use, distribution, and reproduction in any medium, provided the original author and source are credited.



**Figure 3:** 2nd round fixed position scan, outlined GTV2, defined shrinking, made proposal 2.



**Figure 4:** Radiotherapy.

dose, reduced normal tissue toxicity while still yielding significant tumoricidal effect, and complications such as radioactive pneumonia, radioactive esophagitis, etc. had not happened to the patient who survives for a long time after radiotherapy.

## References

- Bradley J, Graham MV, Winter K, Purdy JA, Komaki R, et al. (2005) Toxicity and outcome results of RTOG 9311: a phase I-II dose-escalation study using three-dimensional conformal radiotherapy in patients with inoperable non-small-cell lung carcinoma. *Int J Radiat Oncol Biol Phys* 61: 318-328.
- Erridge SC, Seppenwoolde Y, Muller SH, van Herk M, De Jaeger K, et al. (2003) Portal imaging to assess set-up errors, tumor motion and tumor shrinkage during conformal radiotherapy of non-small cell lung cancer. *Radiother Oncol* 66: 75-85.
- Britton KR, Starkschall G, Tucker SL, Pan T, Nelson C, et al. (2007) Assessment of gross tumor volume regression and motion changes during radiotherapy for non-small-cell lung cancer as measured by four-dimensional computed tomography. *Int J Radiat Oncol Biol Phys* 68: 1036-1046.
- Ramsey CR, Langen KM, Kupelian PA, Scaperroth DD, Meeks SL, et al. (2006) A technique for adaptive image-guided helical tomotherapy for lung cancer. *Int J Radiat Oncol Biol Phys* 64: 1237-1244.
- Woodford C, Yartsev S, Dar AR, Bauman G, Van Dyk J (2007) Adaptive radiotherapy planning on decreasing gross tumor volumes as seen on megavoltage computed tomography images. *Int J Radiat Oncol Biol Phys* 69: 1316-1322.
- Engelsman M, Remeijer P, van Herk M, Lebesque JV, Mijnheer BJ, et al. (2001) Field size reduction enables iso-NTCP escalation of tumor control probability for irradiation of lung tumors. *Int J Radiat Oncol Biol Phys* 51: 1290-1298.
- Feng M, Kong FM, Gross M, Fernando S, Hayman JA, et al. (2009) Using fluorodeoxyglucose positron emission tomography to assess tumor volume during radiotherapy for non-small-cell lung cancer and its potential impact on adaptive dose escalation and normal tissue sparing. *Int J Radiat Oncol Biol Phys* 73: 1228-1234.

pneumonitis, no radiation esophagitis and its complications followed, no tumour regenerated, the patient lives a better life.

## Discussion

This case is a comparatively special example. The patient underwent a complete right-side pulmonary lobectomy twenty years ago, left lung supports compensating breath, the breathing function is relatively poor. Left lung central type squamous cell carcinoma made patient's breathing even more exacerbated. Thus, he can't take any operation medical treatment. 3D-CRT has advantages to local tumor control, many studies find shrinking back at various degrees exists in the tumour during radiotherapy, by reducing the irradiation field, replan the 3D-CRT regimen to reduce the peripheral pulmonary tissue injury [2-5], and Engelsman M et al. [6] found that tumor control of lung tumors might be increased by dose escalation in combination with a reduction of field sizes. Feng M et al. [7] found that tumor metabolic activity and volume can change significantly after 40~50 Gy of RT. Therefore when the GTV dose reached 50 ~ 54 Gy, namely the subclinical lesions under control, second, third CT scan was used, and based on the reduced tumor volume to make 3D-CRT plan, not only can improve the dose of GTV, but also can reduce normal tissue and organ dose. So we applied late course shrinking GTV and boost radiotherapy, maximized GTV