

## A Case Report of Danon Disease

Olusan AA\* and Balachandran KP

Belfast City Hospital, Belfast, Northern Ireland, UK

### Abstract

We present a case of a 21-year-old gentleman with background history of moderate learning disability, Type 1 Diabetes Mellitus and elevated ALT. Due to incidental finding of a double apical impulse and abnormal ECG was referred for cardiology review. His echocardiogram findings triggered a cascade of other investigations which eventually resulted into genetic testing that confirmed Danon disease.

He had a high HCM risk-SCD score and therefore had an ICD implant but unfortunately due to poor diabetic control, he was unlisted from heart transplant list. About 5 years after his formal diagnosis, he developed decompensated and congestive heart failure despite optimal medical therapy. He unfortunately passed away due to end-stage heart failure.

**Keywords:** Echocardiogram (Echo); Sudden Cardiac Death (SCD); Implantable cardioverterdefibrillator (ICD); Hypertrophic Cardiomyopathy (HCM); Lysosomal associated membrane protein 2 (*LAMP 2*); Ventricular tachycardia (VT); New York Heart Association class IV (NYHA IV)

### Introduction

Moderate learning disability, Type 1 diabetes mellitus (24/08/2007). His Father had myocardial infarction at 65 yrs, maternal aunt had myocardial infarction at 72 yrs and grandmother had TIA.

### Case Presentation

We present a case of a 21-year-old male who while under the care of a paediatrician and endocrinologist at the age of 16 years was found to have deranged liver enzymes (raised ALT) in February 2011 but with normal liver ultrasound. Physical examination at that stage demonstrated a double apical impulse, and a subsequent ECG showed sinus rhythm with LVH, bundle branch block morphology with repolarisation abnormality. He was therefore referred for cardiology review at the East Lancashire Hospitals NHS Trust.

He had an echocardiogram which demonstrated severe biventricular hypertrophy, his intraventricular septum and LV posterior wall thickness were 2.3 cm. He was at that stage advised to avoid any strenuous exercise and thus referred for genetic testing for Hypertrophic Cardiomyopathy (HCM) and Fabry's disease on 06/01/2012.

He was referred for a 48 hours holter and supervised exercise treadmill test. His Holter monitor showed sinus rhythm with occasional atrial premature complexes and 5 beats of atrial tachycardia but no evidence of ventricular arrhythmia. He completed a Bruce protocol of 7 minutes but had slight light-headedness associated with blood pressure drop from 145/7 mmHg to 135/75 mmHg and occasional ventricular ectopics.

Due to these results his HCM risk-SCD score was 8.53 (high risk), he was considered for ICD on 20/02/2012 after review in clinic and was therefore started on Bisoprolol and referred for a prophylactic ICD.

He was seen by a Geneticist at Central Manchester University Hospital (CMUH) on 14/05/2012 who suspected Danon disease and blood tests were sent for Lysosomal associated membrane protein 2 (*LAMP 2*) mutation for confirmation of diagnosis and also referred for visual assessment to rule out cone-rod dystrophy (as a complication of Danon).

On 18/05/2012, he was admitted with palpitations and tachyarrhythmia, therefore his  $\beta$ -blocker was optimised.

Meanwhile due to his derange liver enzymes, he was reviewed in gastroenterology clinic on 30/05/2012, but with no abdominal symptoms. Celiac screen and autoantibodies were normal and Liver biopsy was initially suggested but later dropped after his review by geneticist.

On 10/07/2012, he was reviewed in the device clinic at CMUH for consideration for a prophylactic ICD and was therefore accepted for ICD implant.

He was subsequently reviewed by the Geneticist on 26/07/2012 were *LAMP 2* gene was confirmed to have been identified *de-novo* thereby confirming the diagnosis of Danon disease. His sister and mother had negative screening test.

Following this, he had a standard trans-venous and subcutaneous ICD with backup pacing implanted. Subsequent device interrogation at the device clinic found episodes of appropriate shocks for ventricular tachycardia (VT) and also inappropriate shocks. His bisoprolol was thus increased to 2.5 mg bd. Also, he was recommended for heart transplant once his LV starts to deteriorate due to literature evidence on his type variant.

He had an ophthalmology screening for cone-rod dystrophy which was normal on 01/05/2013.

On 21/05/2014, he was admitted with symptoms suggestive of transient ischaemic attack (TIA) due to right arm and facial weakness with dysarthria but with normal CT head, he was thus started on low molecular weight heparin (Tinzaparin) but ICD interrogation showed no evidence of atrial fibrillation. Also, he had a normal coronary angiogram on 26/05/2014.

Unfortunately, several month later, his diabetes became uncontrolled as he was found to be taking lots of sweet treats, dairy milk and unhealthy foods. Due to his uncontrolled diabetes, he was thus suspended from the transplant list on 14/07/2015.

\*Corresponding author: Dr. Adeogo Akinwale Olusan, Belfast City Hospital, Belfast, Northern Ireland, UK, Tel: +44 28 9032 9241; E-mail: [aakinwale@yahoo.co.uk](mailto:aakinwale@yahoo.co.uk)

Received March 12, 2018; Accepted March 24, 2018; Published March 30, 2018

Citation: Olusan AA, Balachandran KP (2018) A Case Report of Danon Disease. J Clin Case Rep 8: 1089. doi: [10.4172/2165-7920.10001089](https://doi.org/10.4172/2165-7920.10001089)

Copyright: © 2018 Olusan AA, et al. This is an open-access article distributed under the terms of the Creative Commons Attribution License, which permits unrestricted use, distribution, and reproduction in any medium, provided the original author and source are credited.

On 11/07/2016, he was reviewed by his GP due to orthopnoea and peripheral oedema. His pro-BNP was elevated at 10,564, he was therefore started on Furosemide and referred for cardiology review as outpatient.

On 29/07/2016, he was reviewed in cardiology outpatient clinic with few months' history of orthopnoea, weight gain, peripheral oedema and ascites. His JVP was elevated to the mandibular angle. He was diagnosed with NYHA IV, furosemide was increased to 80 mg and thus referred for ambulatory heart failure treatment. 2 months later (21/09/2016) he was admitted again with similar symptoms and had gained 13 kg extra weight. His diuretics was optimised (Furosemide 250 mg/24 hours increased to 350 mg/24 hours and alternate day metolazone and spironolactone). Subsequent echo showed poor LVSF. 8 days after his admission he developed end-stage heart failure, deteriorated despite maximum medical treatment and unfortunately passed away on 04/10/2016.

### Investigations

Liver enzymes- Elevated ALT (>700). Liver ultrasound- Normal. ECG- Sinus rhythm with LVH, Bundle branch block and repolarisation abnormality. Initial echocardiography (2012)- Concentric severe LVH and RVH; IVSD and LVPW thickness was 2.3 cm. 48-hour Holter monitor (2012)- Sinus rhythm with occasional atrial premature complexes and 5 beats of atrial tachycardia but no evidence of ventricular arrhythmia (Figures 1-3).

Exercise treadmill test (2012)- Bruce protocol of 7 minutes but had slight light-headedness associated with blood pressure drop from 145/7 mmHg to 135/75 mmHg and occasional ventricular ectopics. Coeliac screen and autoantibodies- Normal. Lysosomal associated membrane protein 2 (*LAMP 2*) mutation- Positive. ICD interrogation - Episodes of appropriate shocks for ventricular tachycardia (VT) and also inappropriate shocks. Ophthalmology screening for cone-rod dystrophy - Normal.

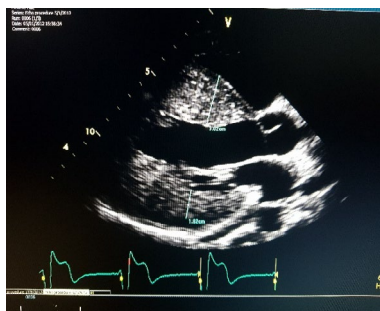


Figure 1: Showing severe concentric LVH (PLAX view).

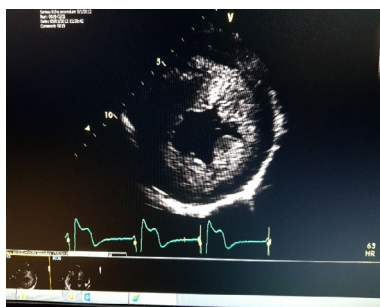


Figure 2: Showing severe concentric LVH (PSAX view).

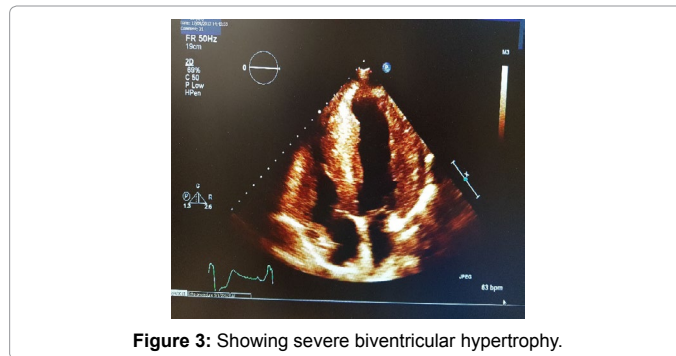


Figure 3: Showing severe biventricular hypertrophy.

CT head- Normal. Coronary angiogram- Normal. HbA1c -very high (>130). Last echocardiography (2016)- Poor LV systolic function.

### Discussion

#### Differential diagnosis

Pompe disease, Fabry's disease, X-linked vacuolar myopathy with excessive autophagy (XMEA), Infantile autophagic vacuolar myopathy, PRKAG2 mutation form of HCM, WPW syndrome, DCM, Restrictive Cardiomyopathy.

#### Treatment

Bisoprolol, ICD implant, Furosemide, Metolazone and Spironolactone. Heart transplant.

#### Outcome and follow up

As Danon disease has a poor prognosis, he was recommended for a heart transplant. But due to his poor diabetic control he was suspended and then unlisted. Unfortunately, despite optimal medical therapy he passed away.

### Conclusion

Danon disease is an X-linked disorder due to mutations in the gene encoding lysosomal-associated membrane protein 2 (*LAMP 2*). It is also called glycogen storage disease type 2B, lysosomal glycogen storage disease with normal acid maltase and formerly called idiopathic hypertrophic subaortic stenosis (IHSS).

It is characterised by cardiomyopathy, skeletal myopathy, some degree of learning disability. It presents in young patients, clinically similar to severe hypertrophic cardiomyopathy (HCM) resulting into accelerated cardiac disease progression often resulting in premature deaths <25 years old age [2,3]. Unlike in males, female patients most often present with late-onset cardiomyopathy and slow disease progression [4-6] while male have very poor prognosis. The incidence of the disease has not been determined while the exact prevalence is unknown.

Patients are often affected with conduction abnormality predisposing to cardiac pre-excitation (WPW pattern). Skeletal myopathy occurs in most male patient and half of affected female patients. This involves upper arms, shoulders, neck and upper thighs with resulting elevated creatine kinase (CK) levels. All patients would require an ICD due to high SCD risk score. The importance of early molecular diagnosis for prognosis prediction and early consideration of heart transplantation cannot be overemphasized [7-9].

#### Learning Points/Take Home Messages

Strong clinical suspicion when patient has learning disability, hypertrophic cardiomyopathy and skeletal dystrophy.

## References

1. Case report taken from East Lancashire Hospitals NHS Trust (United Kingdom).
2. Majer F, Vlaskova H, Krol L, Kalina T, Kubanet M, et al. (2012) Danon disease: A focus on processing of the novel LAMP2 mutation and comments on the beneficial use of peripheral white blood cells in the diagnosis of LAMP2 deficiency 498: 183-195.
3. Maron BJ, Roberts WC, Arad M, Haas TS, Spirito P, et al. (2009) Clinical outcome and phenotypical expression in LAMP2 cardiomyopathy. JAMA 301: 1253-1259.
4. Bottillo I, Giordano C, Cerbelli B, D'Angelantonio D, Lipari M, et al. (2016) A novel LAMP2 mutation associated with severe cardiac hypertrophy and microvascular remodelling in female with Danon disease: a case report and literature review. Elsevier, Cardiovasc Pathol 25: 423-431.
5. Vaux KK (2016) Danon Disease. Drug Diseases.
6. Boucek D, Jirikowic J, Taylor M (2011) Natural history of Danon disease. Genet Med 13: 563-8.
7. Thiadens AA, Slingerland NW, Florijn RJ, Visser GH, Riemsdag FC, et al. (2012) Cone – rod dystrophy can be a manifestation of Danon disease. Graefes Arch Clin Exp Ophthalmol 250: 269-74.
8. Siland J, van der EY, Tromp J, Marcos E, Pieper PG (2014) ESC Guidelines on diagnosis and management of hypertrophic cardiomyopathy. The Task Force for the Diagnosis and Management of Hypertrophic Cardiomyopathy of the European Socie. Eur Heart J 35.
9. O'Mahony C, Jichi F, Pavlou M, Monserrat L, Anastasakis A et al. (2014) A novel clinical risk prediction model for sudden cardiac death in hypertrophic cardiomyopathy (HCM Risk – SCD). Eur Heart J 35: 2010-2020.