

# A Case Report of a Severely Immunocompromised Patient with Clinically Amyopathic Dermatomyositis-related ILD: Is CMV-prevention Indicated?

Bernhard AE<sup>1</sup>, Leavis HL<sup>2</sup>, Verduyn Luynel FM<sup>3</sup>, Mohamed Hoesein FAA<sup>4</sup>, Voortman M<sup>1</sup> and Kwakkel-van Erp JM<sup>5\*</sup>

<sup>1</sup>Department of Respiratory Medicine, University Medical Center Utrecht, Utrecht, The Netherlands

<sup>2</sup>Department of Rheumatology and Clinical Immunology, University Medical Center Utrecht, Utrecht, The Netherlands

<sup>3</sup>Department of Medical Microbiology, University Medical Center Utrecht, Utrecht, The Netherlands

<sup>4</sup>Department of Radiology, University Medical Center Utrecht, Utrecht, The Netherlands

<sup>5</sup>Department of Pulmonology, University Hospital Antwerpen (UZA), Edegem, Belgium

## Abstract

We herein report a case of a 59-year old female with rapidly progressive interstitial lung disease due to anti-MDA-5 positive clinically amyopathic dermatomyositis. Despite initial response to a combination high dose immunosuppressive treatment, her respiratory condition deteriorated and she was screened for urgent lung transplantation. During screening an active CMV-infection was revealed, which made her ineligible for the procedure. Unfortunately, despite CMV treatment, the patient died due to her pulmonary condition. Since more aggressive immunosuppressive regimens increase risk of viral reactivation, and after reviewing the literature, we debated if in analogue with solid organ transplantation, CMV prevention or monitoring should be applied to optimize clinical outcome.

**Keywords:** CMV; Anti-MDA5; Dermatomyositis; Lung transplantation

## Introduction

Dermatomyositis is a rare autoimmune deficit characterized by skin abnormalities and muscle weakness. In addition to the classic dermatomyositis, there is a subtype without muscle weakness: Clinically amyopathic dermatomyositis (CADM) [1]. Treatment consists of prednisone and if needed immunosuppressive drugs can be added [2]. One of the feared complications of dermatomyositis is interstitial lung disease (ILD), which occurs in approximately 28% of the patients [1].

Patients with CADM and especially patients positive for anti-melanoma-differentiation-associated protein-5 (anti-MDA-5) which is an auto-antibody present in 13% of the patients with CADM, have a high risk for rapidly progressive ILD which is refractory to intensive therapy and leads to poor survival rates due to a high risk for rapidly progressive ILD [1]. Anti-MDA-5 recognizes the melanoma-differentiation-associated protein-5 (MDA-5), which plays a role in the innate immune system, identifying RNA viruses and producing type I interferons and proinflammatory cytokines [3]. Although the pathophysiology of anti-MDA-5 in dermatomyositis-related ILD has not been elucidated yet, the titer in the blood seems to be closely correlated to disease activity and outcome.

Due to poor outcomes, aggressive treatment with immunosuppressive drugs is assumed to be imperative to slow down the progression of the ILD [4]. However, intensive immune suppressive treatment increases the risk for infections, such as viral reactivations. Some infection prophylactic treatment is accepted standard care in severely immunocompromised patients with pre-existing lung disease, such as PJP prophylaxis or bacterial prophylaxis. Therefore the question is raised if intensive immunosuppressive treatment should be accompanied by monitoring of and prophylaxis for viral reactivations. Here we discuss a case in which cytomegalovirus (CMV) reactivation was detected during severe disease manifestations.

## Case Presentation

A 59-year old female was admitted to our tertiary medical center because of arthritis (progressive arthralgia and swollen joints) and

progressive dyspnea which were unresponsive to initial treatment with both oral and intravenous prednisone. She was a non-smoker, and her family history was negative for lung diseases or auto-immune disorders.

High Resolution Computer Tomography (HRCT) revealed ground glass opacities compatible with a nonspecific interstitial pneumonia (NSIP) that rapidly progressed into an organizing pneumonia, as frequently observed in a rapidly progressive CADM (Figure 1). The pulmonary function test showed a restrictive pattern (Figure 2). Analysis of blood showed normal leucocytes, normal C-reactive protein (CRP), negative ANA and serology compatible with latency for EBV and CMV (negative polymerase chain reaction (PCR)).

A strongly positive MDA-5 antibody level confirmed the diagnosis of an anti-MDA-5+ CADM with a rapidly progressive ILD. The patient was treated with a combination of a 3-day course of pulse methylprednisolone (1000 mg/day) and pulse cyclophosphamide (750 mg/m<sup>2</sup>) followed by oral prednisone.

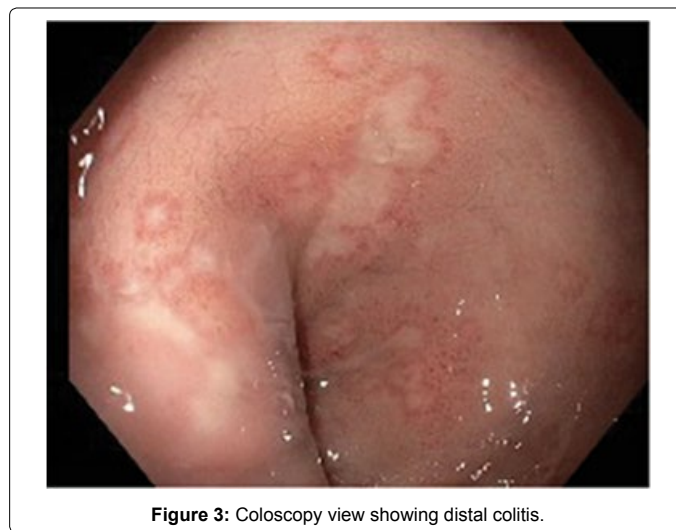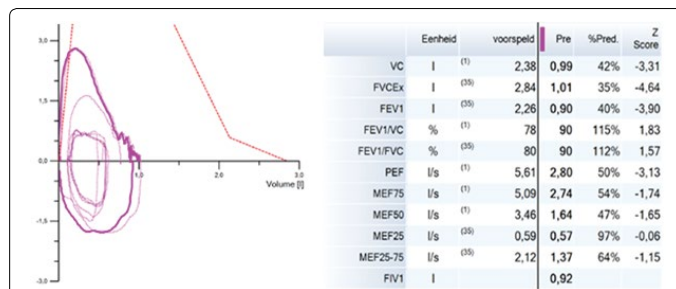
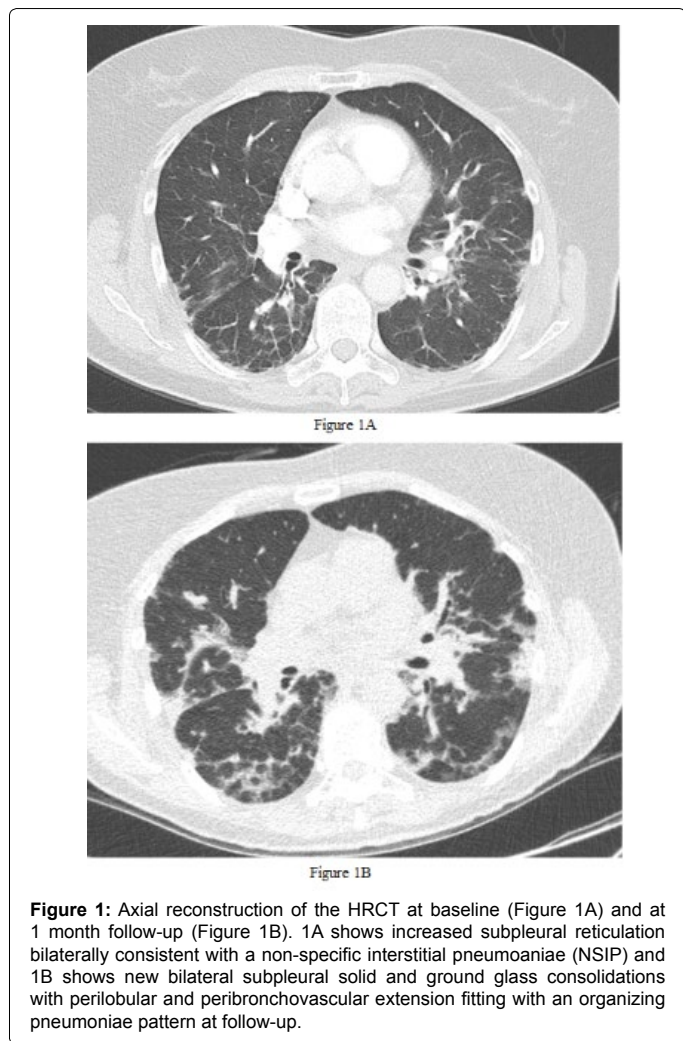
Initially, the dyspnea improved, but after a few weeks desaturations started to occur. Radiologic imaging revealed progressive consolidations compatible with therapy failure, and she was treated with antibiotics and screened for urgent lung transplantation. Medical treatment for her rapidly progressive ILD was switched to rituximab (375 mg/m<sup>2</sup>) weekly and tacrolimus 3 mg twice daily dose-adjusted for a target trough level of 5-10 ng/ml) was started and pneumocystis jirovecii pneumonia (PJP) prophylaxis was started.

**\*Corresponding author:** Johanna Kwakkel-van Erp, Department of Pulmonology, University Hospital Antwerpen (UZA), Edegem, Belgium, Tel: +32468040187, Fax: +3238214447; E-mail: [Johanna.Kwakkel-vanErp@uza.be](mailto:Johanna.Kwakkel-vanErp@uza.be)

**Received** November 08, 2018; **Accepted** November 14, 2018; **Published** November 21, 2018

**Citation:** Bernhard AE, Leavis HL, Verduyn Luynel FM, Mohamed Hoesein FAA, Voortman M, et al. (2018) A Case Report of a Severely Immunocompromised Patient with Clinically Amyopathic Dermatomyositis-related ILD: Is CMV-prevention Indicated?. J Pulm Respir Med 8: 480. doi: [10.4172/2161-105X.1000480](https://doi.org/10.4172/2161-105X.1000480)

**Copyright:** ©2018 Bernhard AE, et al. This is an open-access article distributed under the terms of the Creative Commons Attribution License, which permits unrestricted use, distribution, and reproduction in any medium, provided the original author and source are credited.



During transplantation work-up, 1 months within extensive immunosuppression, CMV-copies in the blood increased from <200 to 676 IU/ml (QPCR). Despite normal peripheral blood leucocyte counts (8.7-6.4 x 10<sup>9</sup>) lymphocytes decreased from 1.58 to 0.38 x 10<sup>9</sup>/L. Due to persistent diarrhea despite adequate treatment for *Clostridium difficile*, a colonoscopy was performed showing a distal colitis (Figure 3). In the presence of CMV in plasma, a clear differentiation between CMV end-organ diseases, including colitis and pneumonitis, or an asymptomatic reactivation could not be made and therefore treatment with valganciclovir was initiated. However, despite antiviral treatment, her pulmonary situation further deteriorated and she died. Autopsy showed alveolar damage due to interstitial pneumonia without signs of CMV disease and bacterial cultures remained negative. Unfortunately, no consent was given for complete autopsy.

## Discussion

Dermatomyositis can result in potentially life-threatening ILD, especially in case of MDA-5+ CADM [1,4]. The progressive component encountered in a dermatomyositis is commonly an organising pneumonia as seen in this case report. High doses of immunosuppressive drugs are used to control progression of the disease, but if this fails, lung transplantation is the ultimate lifesaving therapy. In this case, despite the aggressive treatment regimen, patient further deteriorated. In addition she developed an active CMV-infection.

CMV is a DNA virus which belongs to the *herpesviridae* and is a member of the subfamily of *betaherpesvirinae*. After primary infection, the virus remains latently present in the body being controlled by the adaptive immunessystem in immunocompetent patients. This is a common situation, with a CMV-seroprevalence of 30%-70% in the general population [5]. CMV may reactivate and cause infection when the immune system is impaired. CMV-infection is diagnosed when CMV is isolated or particles are detected in any type of body fluid [5,6]. CMV-disease, describes the situation when one or more end-organs are affected, and is defined as the combination of clinical symptoms and CMV-presence in the tissue of the affected organ [6]. Symptoms of CMV disease may include flu-like complaints such as fatigue, fever and bone marrow suppression (generally leukopenia and neutropenia) but does also include end-organ disease such as colitis, pneumonitis, hepatitis, nephritis, myocarditis, retinitis and central nervous system involvement. CMV-disease is almost exclusively seen in immunocompromised hosts, and is associated with significant morbidity and even mortality [5,6].

Our patient died due to hypoxic respiratory failure as a result of a fulminant progressive interstitial lung disease. Unfortunately, the combination of colitis and CMV reactivation in her plasma made her ineligible for transplantation. In our lung transplant protocol we routinely prescribe valganciclovir iv in therapeutic doses for five days post-transplant if donor or recipient is CMV positive. Therefore CMV reactivation is not a strict contra indication for lung transplantation. Nevertheless, with the use of aggressive immunosuppressive treatment and the prevalence of CMV one can speculate if CMV-prophylaxis or CMV-monitoring is appropriate in addition to prophylaxis against other opportunistic infections like PJP. In the solid-organ transplantation setting, where CMV infection is a fearful complication, preventive

strategies play an important role [7].

After solid organ transplantation, CMV-prevention is commenced by either starting universal antiviral prophylaxis with (val) ganciclovir directly after transplantation for a duration of 3-6 months, or by a preemptive strategy, which consists of monitoring viral DNA replication in the patient's blood, allowing to start antiviral treatment immediately when the virus reactivates in order to avoid clinical disease. Prophylaxis with antiviral medication has substantial negative side effects due to drug toxicity, of which the most important is neutropenia and leukopenia [7]. As for solid organ transplantation, the problem is not just the direct effects of CMV infection, but also the indirect effects that affect the transplanted organ, such as rejection and graft loss [8]. These problems do not apply to the non-transplant patients.

Although there is a high incidence of CMV-seroprevalence, with a potential risk for reactivation when the immune system is weakened, the actual risk for a non-transplant immunosuppressed patient to acquire a CMV-infection is unknown [5]. It is also unknown whether initial asymptomatic CMV reactivation progresses to CMV end-organ disease in these patients. Few small and retrospective studies have tried to gain some insight in the relation between CMV and autoimmune diseases and showed that CMV-infection in autoimmune disease patients is associated with immunosuppressive treatment, lymphopenia and the presence of other infections [9,10]. However, it remains unknown whether prophylaxis of CMV reactivation improves outcomes for these patients. Furthermore it is unknown when to start antiviral treatment of asymptomatic CMV reactivation to prevent end-organ disease and whether this ultimately improves the outcome for these patients. A recently published study failed to show a positive effect of ganciclovir prophylaxis in non-immunocompromised ICU patients. Further studies are needed to elucidate the role of CMV on the outcome in immunosuppressed non-transplant patients and whether antiviral treatment is beneficial in case of CMV reactivation. Another option could be to monitor viral DNA replication in the patient's blood, allowing to start antiviral treatment immediately when the virus reactivates or to suppress the immunosuppressive regimen. It has been postulated that CMV reactivation may occur in lymphopenic patients but until now this hypothesis has not been studied yet in prospective studies.

## Conclusion

Our patient with an anti-MDA-5+ CADM with rapidly progressive

ILD, despite intensive combination of immunosuppressive treatment was therapy refractory. Unfortunately, she also developed a CMV-infection which made her ineligible for lung transplantation and died. Although PBL counts were normal, she developed a lymphocytopenia. In these cases of severely ill immunocompromised patients CMV monitoring and early treatment may be useful. However, more research is needed to test this hypothesis. From a clinical view, it is important to stay attentive for CMV-infection when prescribing high doses of immunosuppressive drugs, especially considering the high incidence of CMV-seropositivity, the often vague and general symptoms and the potentially serious consequences of CMV-infection.

## Conflict of Interest

The authors declare they have no conflict of interest.

## References

1. Moghadam-Kia S, Oddis CV, Sato S, Kuwana M, Aggarwal R (2016) Anti-melanoma differentiation-associated gene 5 is associated with rapidly progressive lung disease and poor survival in us patients with amyopathic and myopathic dermatomyositis. *Arthritis Care Res* 68: 689-694.
2. Aggarwal R, Oddis CV (2012) Therapeutic advances in myositis. *Curr Opin Rheumatol* 24: 635-641.
3. Kato H, Takeuchi O, Sato S, Yoneyama M, Yamamoto M, et al. (2006) Differential roles of MDA5 and RIG-I helicases in the recognition of RNA viruses. *Nature* 441: 101-105.
4. Marie I, Hatron PY, Dominique S, Cherin P, Mouthon L, et al. (2011) Short-term and long-term outcomes of interstitial lung disease in polymyositis and dermatomyositis: A series of 107 patients. *Arthritis Rheum* 63: 3439-3447.
5. Gandhi MK, Khanna R (2004) Human cytomegalovirus: Clinical aspects, immune regulation, and emerging treatments. *Lancet Infect Dis* 4: 725-738.
6. Ljungman P, Boeckh M, Hirsch HH, Josephson F, Lundgren J, et al. (2017) Definitions of cytomegalovirus infection and disease in transplant patients for use in clinical trials. *Clin Infect Dis* 64: 87-91.
7. Ramanan P, Razonable RR (2013) Cytomegalovirus infections in solid organ transplantation: A review. *Infect Chemother* 45: 260-271.
8. Roman A, Manito N, Campistol JM, Cuervas-Mons V, Almenar L, et al. (2014) ATOS working group. The impact of the prevention strategies on the indirect effects of CMV infection in solid organ transplant recipients. *Transplant Rev* 28: 84-91.
9. Tsai WP, Chen MH, Lee MH, Yu KH, Wu MW, et al. (2012) Cytomegalovirus infection causes morbidity and mortality in patients with autoimmune diseases, particularly systemic lupus: In a Chinese population in Taiwan. *Rheumatol Int* 32: 2901-2908.
10. Takizawa Y, Inokuma S, Tanaka Y, Saito K, Atsumi T, et al. (2008) Clinical characteristics of cytomegalovirus infection in rheumatic diseases: Multicentre survey in a large patient population. *Rheumatol* 47: 1373-1378.