

A Case Report of A 51-Year-Old Male with Past Medical History of Adrenomyeloneuropathy Requiring a Video-Assisted Thoracic Surgery for a Left Parapneumonic Empyema

Cassandra Wasson* and Albert Kelly

Riverside University Health System, California, United States

*Corresponding author: Cassandra Wasson, DO, Anesthesiology, Resident Physician, Riverside University Health System, 26520 Cactus Ave, Moreno Valley, CA 92555, United States, Tel: 8145736815; E-mail: cassie_wasson@yahoo.com

Received: November 01, 2017, Accepted: December 02, 2017, Published: December 11, 2017

Copyright: © 2017 Wasson C, et al. This is an open-access article distributed under the terms of the Creative Commons Attribution License, which permits unrestricted use, distribution, and reproduction in any medium, provided the original author and source are credited.

Abstract

51-year-old male with adrenomyeloneuropathy required a video-assisted thorascopic surgery (VATS) for left parapneumonic empyema, likely from recurrent micro-aspirations. General anesthesia and surgery were uneventful. The patient met extubation criteria and was transferred to the intensive care unit (ICU). He required re-intubation post-operatively for hypoxemia and was started on total parenteral nutrition (TPN) and a propofol infusion. He continued to weaken post-operatively, received a percutaneous gastrostomy tube and a tracheostomy, and was transferred to a long-term acute care facility. A poor understanding of the pharmacokinetics of propofol and TPN on adrenomyeloneuropathy may have caused the rapid progression of this rare disease.

Keywords Adrenomyeloneuropathy; Adrenoleukodystrophy; Peroxisome

Introduction

Adrenomyeloneuropathy is a rare, progressive, x-linked recessive neuro-degenerative, metabolic disorder due to mutations in the ABCD1 gene located on the X-chromosome. It leads to an absence or dysfunction of the adrenoleukodystrophy protein (ALDP), which is a peroxisomal transmembrane protein that transports very long-chain fatty acids from the cytosol into the peroxisome [1,2]. Without this protein, very long-chain fatty acids accumulate in the plasma and deposit in all tissues of these patients, including the white matter of the brain, the spinal cord, and the adrenal cortex [2]. This causes the symptoms these patients often experience: muscle weakness, gait imbalance (due to sensory ataxia), bladder dysfunction, adrenal insufficiency, spastic paraparesis, hypertonia, dysarthria, sexual dysfunction, mild peripheral neuropathy, weight loss, and nausea [1-3]. The brain is involved in a minority of cases, which causes symptoms of behavioral changes, vision loss, hearing problems, and/or seizures [2,3].

Case Presentation

A 51-year-old male with history of adrenomyeloneuropathy (bed-bound for two years), fatty liver disease, and severe malnutrition presented to the emergency department (ED) with a left tension pneumothorax, bilateral submassive pulmonary embolisms, and community-acquired pneumonia (Figure 1). A left thoracostomy tube was placed in the ED and a heparin drip (gtt), norepinephrine gtt, and empiric antibiotics were started. The patient was admitted to the medicine intensive care unit (ICU) for management of septic shock. After admission, his bilateral pleural effusions continued to increase in size (Figure 2) and interventional radiology (IR) was consulted. IR placed one right and two left pigtales for drainage.

The patient was noted to have poor oral intake, so total parenteral nutrition (TPN) was started. His pleural effusions persisted, so intrapleural fibrinolytic therapy was attempted. It failed, leading to a surgical consult for this patient's persistent pleural fluid. Surgery placed a thoracostomy tube in the right pleural effusion. The patient's left pleural fluid appeared to be a parapneumonic empyema (Figure 3), so surgery scheduled the patient for a video-assisted thoracic surgery (VATS). Pre-operative stress dose hydrocortisone 100 milligrams (mg) intravenous (IV) was given by anesthesia. No pre-operative sedation was given for fear of respiratory suppression. The patient was induced with fentanyl (100 micrograms (mcg) IV), propofol (50 mg IV), and rocuronium (50 mg IV). He was intubated with a double-lumen tube and an arterial line was placed. He was maintained with sevoflurane and fentanyl (total of 250 mcg IV) intra-operatively without additional paralytics. He tolerated the VATS well and paralytics were reversed. He met extubation criteria, was extubated, and was transferred to ICU. After arrival in the ICU, the patient began to desaturate and became hypotensive. He was subsequently re-intubated. The patient self-extubated overnight and, again, was re-intubated for desaturations. Sedation was maintained with propofol and fentanyl gtt. Post-operative day two, he was found to have new onset exotropia. Head computerized tomography (CT) was done and showed moderate to severe parenchymal atrophy atypical for a 51-year-old, but was otherwise unremarkable. The patient continued to require ventilator support throughout his hospitalization. He subsequently received a percutaneous endoscopic gastrostomy (PEG) tube and tracheostomy and was transferred to a long-term care facility.

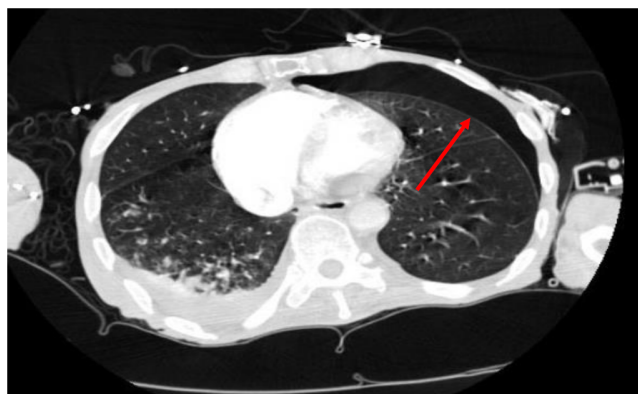

Figure 1: Emergency department chest computerized tomography. Notice the bilateral severe chronic lung disease and left pneumothorax (red arrow).

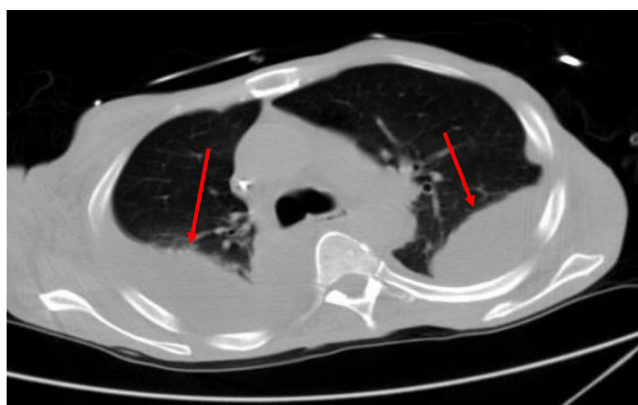


Figure 2: Chest computerized tomography day seven of hospitalization. Notice the bilateral large pleural effusions (red arrows).

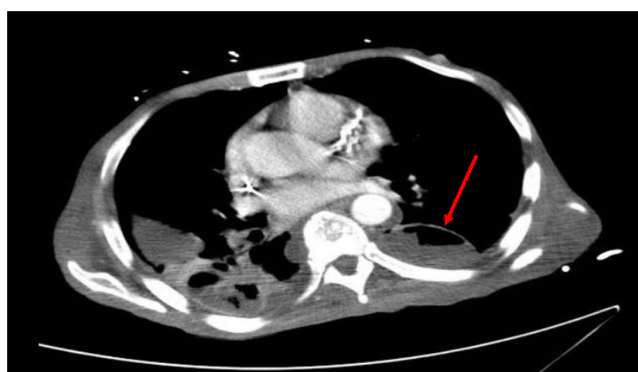

Figure 3: Chest computerized tomography day eleven of hospitalization demonstrating left parapneumonic empyema (red arrow).

Discussion and Conclusion

During our literature research, no case reports of adrenomyeloneuropathy were found in the anesthesia literature. Adrenomyeloneuropathy patients are prone to respiratory depression, so pre-operative sedation should be avoided [4], as was done in this case. The response of these patients to non-depolarizing paralytics is unknown; clinical monitoring is imperative to guide administration [4]. Succinylcholine should be used with caution as the majority of these patients are bedbound, leading to an increased risk of hyperkalemia and possible cardiac arrest post-succinylcholine usage [4]. These patients are also at increased risk of osteoporosis due to chronic steroid therapy, hypogonadism, and immobilization, predisposing them to iatrogenic fractures during transfer and positioning [4]. Lastly, these patients often have adrenal suppression due to accumulation of fatty acids in the adrenal glands [1-3]. Therefore, these patients are treated with exogenous steroids and require stress dose steroids with the subsequent steroid taper post-operatively. This was successfully completed in this patient.

As propofol contains very long chain fatty acids and these patients are unable to transport them, propofol may not be the best induction or sedation medication for this disease. Etomidate may have been a better induction agent for this patient. It is well known that etomidate causes adrenal suppression, but these patients have adrenal insufficiency and are receiving exogenous steroids, so the risk of this agent would be minimal. Similarly, a different agent for sedation, such as dexmedetomidate, may have been a better choice than propofol. Additionally, this patient was started on TPN early in his hospital course. TPN also contains very long chain fatty acids and may have contributed to the progression of this patient's disease. Placement of a nasogastric tube or earlier PEG placement with enteral feeds may have been more appropriate for this patient than TPN.

As anesthesiologists, we are responsible for our patients peri-operatively, not solely intra-operatively. We need to prepare not only for the surgical case, but for each individual patient and their comorbidities. We need to know their comorbidities and how our medications may impact each disease process. Remember to not have your blinders on but, rather, look for all possible causes of new exam findings. This patient's bilateral ocular extrophy on post-operative day two was likely due to progression of his adrenomyeloneuropathy. A head CT was done to rule-out stroke, but nobody thought to discontinue the propofol gtt or TPN to decrease the amount of fatty acids circulating in his blood stream. Speculatively, these fatty acids accumulated in his glial cells and caused damage to his ocular nerves, causing his new physical exam findings. Other findings of excess fatty acids were evident by his increasing aspartate aminotransferase and alanine aminotransferase after the start of TPN, with the rate being amplified after the addition of the propofol gtt, and the subsequent down-trending of the enzymes after these medications were discontinued (Figure 4). Remember, the excess fatty acids accumulate in all organs and tissues in these patients. This patient was known to have fatty liver disease pre-operatively. He did not have any risk factors for it (he was not obese, did not have dyslipidemia, and did not have diabetes). He simply had excess fatty acids in his bloodstream that likely accumulated in his liver leading to his fatty liver disease. Advocate for your patients and their post-operative course, especially those who cannot advocate for themselves. This patient's adrenomyeloneuropathy possibly progressed quicker due to the TPN and propofol infusion. If we had better anticipated and understood the

effects of these medications on his chronic disease processes, his post-operative course may have been different.

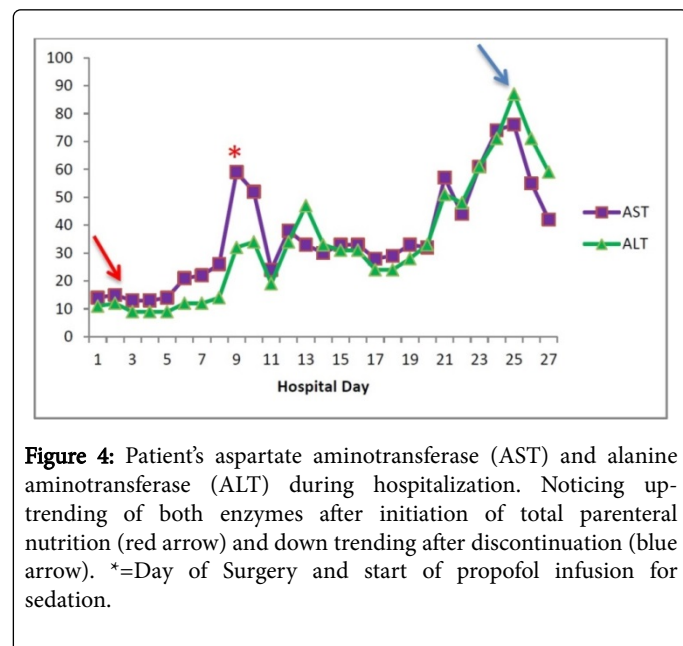


Figure 4: Patient's aspartate aminotransferase (AST) and alanine aminotransferase (ALT) during hospitalization. Noticing up-trending of both enzymes after initiation of total parenteral nutrition (red arrow) and down trending after discontinuation (blue arrow). *=Day of Surgery and start of propofol infusion for sedation.

Disclosure

The patient provided written consent to publish this case report.

References

1. Engelen M, Kemp S, de Visser M, van Geel BM, Wanders RJ, et al. (2012) X-linked adrenoleukodystrophy (X-ALD): clinical presentation and guidelines for diagnosis, follow-up and management. *Orphanet J Rare Dis* 7: 51-64.
2. <https://rarediseases.info.nih.gov/diseases/10614/adrenomyeloneuropathy>
3. <http://myelin.org/amn-adrenomyeloneuropathy/>
4. Kindopp AS, Ashbury T (1998) Anaesthetic management of an adult patient with X-linked adrenoleukodystrophy. *Can J Anaesth* 45: 990-992.