

A Case Report: An Unusual Case of Central Ossifying Fibroma

Samiksha Acharya^{1*}, Vidya K Lohe² and Rahul R Bhowate²

¹Sharad Pawar Dental College and Hospital, Sawangi, Maharashtra, India

²Department of Oral Medicine and Radiology, Sharad Pawar Dental College and Hospital, Maharashtra, India

*Corresponding author: Samiksha Acharya, Final year MDS student, Sharad Pawar Dental College and Hospital, DMIMS (DU), Sawangi (M), Wardha, Maharashtra, India, Tel: 9503279165; Fax: 07152287731; E-mail: smkacharya@gmail.com

Rec date: Apr 21 2016; Acc date: May 26, 2016; Pub date: May 30, 2016

Copyright: © 2016 Acharya S, et al. This is an open-access article distributed under the terms of the Creative Commons Attribution License, which permits unrestricted use, distribution, and reproduction in any medium, provided the original author and source are credited.

Abstract

Central ossifying fibroma is a benign slow-growing tumor of mesenchymal origin and it tends to occur in the second and third decades of life, with predilection for women and for the mandibular premolar and molar areas. Clinically, it is a large asymptomatic tumor of aggressive appearance, with possible tooth displacement. Occasionally treated by curettage enucleation, this conservative surgical excision is showing a recurrence rate extremely low. The following article reports a case of a 13-year-old male patient, who presented with a very large ossifying fibroma in the maxilla, which was successfully treated by surgical intervention. A brief literature review of this lesion, focusing on the histology, clinical behavior, and management of these uncommon lesions is also conducted.

Keywords: Central ossifying fibroma; Fibro osseous lesion; Ossifying fibroma

Introduction

Central ossifying fibroma (COF) is a benign osseous neoplasm which consists of highly cellular, fibrous tissue with varying amounts of calcified tissue, which resembles the bone, the cementum or both [1]. COF is the most common benign fibro osseous neoplasm of the oral and maxillofacial region. It was described by Menzel in 1872 but was appointed by Montgomery in 1927. Fibro-osseous lesions is a term used for a group of diseases of the jaws in which the normal bone tissue is replaced by fibroblasts and fibrous tissue, with formation of variable amounts of mineralized material [2]. This lesion tends to occur in the second and third decades of life, commonly in women, and in the mandibular premolar and molar areas [1]. COF very closely resembles lesions such as fibrous dysplasia, cementifying periapical dysplasia or cemento-osseous florid dysplasia. COF is believed to originate from the

Periodontal membrane [3]. Radio graphically, COF presents as a well-defined, unilocular lesion which contains varying amounts of radiopaque material [4]. Once it is completely excised, COF does not usually recur [5]. Here, we are reporting an unusual case of COF in the left side of the mandible.

Case Report

A 13-year-old male patient reported to the Department of Oral Medicine and Radiology, Sharad Pawar Dental College, Datta Meghe Institute of Medical Science's (Deemed University) Sawangi (Meghe) Wardha, India, with a chief complaint of "swelling" on upper right posterior region of jaw since 2 months. The history of present illness revealed that the swelling was small in size and gradually increased to the present size of 3 × 2 cm approximately. The swelling was not associated with pain previously and now patient complains of pain in the same region, which is dull, aching and intermittent in nature since 1-2 days. Patient gave history of difficulty in mastication due to

presence of diffuse swelling. Patient gave no history of paresthesia, no history of bleeding or any other discharge from the swelling. There was no history of change in size of swelling before or during meal times. The patient was in apparently good health and her medical and dental history was not contributory. On inspection extra oral examination revealed a single diffuse swelling of size 3 × 2 cm approximately, shape was roughly oval, margins were diffuse, and color was same as adjacent mucosa. On palpation all the inspector findings were confirmed regarding size and shape and local temperature was not raised. Swelling was firm to bony hard in consistency, non-tender. Intra-oral examination revealed that, it was covered by a mucosa of normal texture and color (Figure 1).

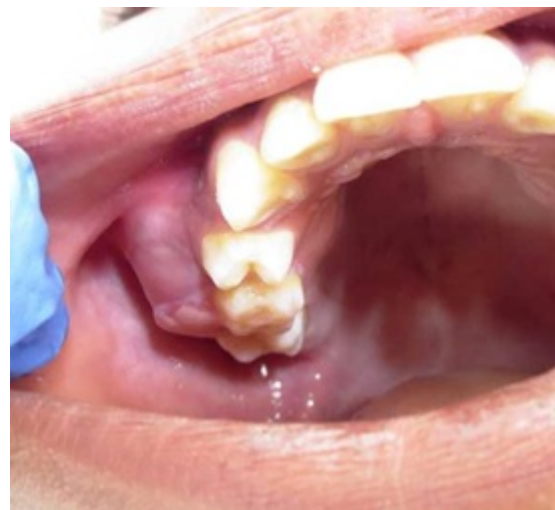

Figure 1: Extra oral examination.

On digital palpation, the swelling was non-tender, non-fluctuant, and firm to bony hard in consistency. The swelling had ill-defined margins. There was no sign of hypoesthesia or paresthesia of the area

involved. So we came to the provisional diagnosis of adenomatoid odontogenic tumor and ossifying fibroma was kept in the differential diagnosis. The occlusal radiograph revealed that a well-defined mixed radiopaque and radiolucent lesion in right maxillary premolar region with superiorly displaced second premolar and the periphery of the lesion is well defined with multilocular radiolucency (Figure 2).

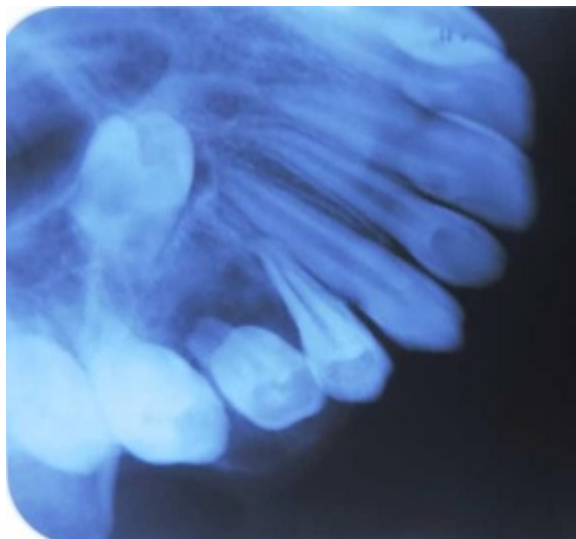


Figure 2: Multilocular radiolucency.

The lesion was excised through an intraoral approach. The tumor was found to be well encapsulated with a cleavage plane to allow it to be shelled out from its surrounding structures. surgical enucleation and osseous recontouring under general anesthesia was done (Figure 3).

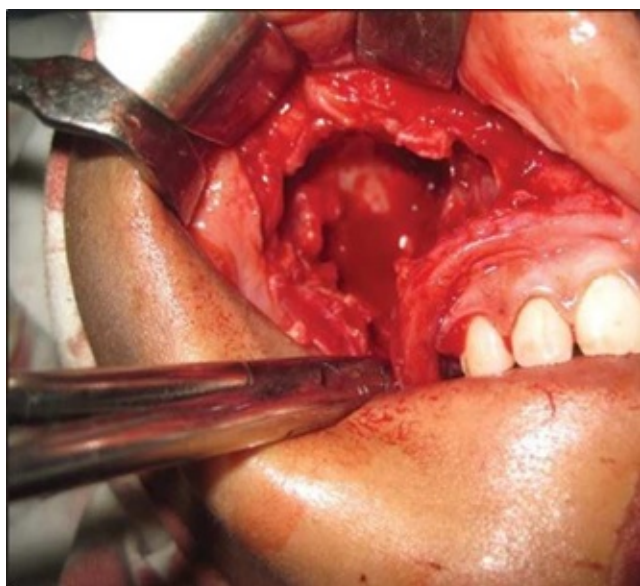


Figure 3: Surgical enucleation and osseous recontouring under general anesthesia.

Histological examination showed that the lesion was distinctly separated from surrounding unaffected bone sometimes by capsule. Osteoblastic rimming was seen. Bony trabeculae were not separated from connective tissue stroma. Bony trabeculae arranged haphazardly. A mixture of osteoid, woven and lamellar bone was seen suggestive of central ossifying Fibroma (Figure 4). Patient was on regular follow up postoperatively for 1 year and no evidence of recurrence noted.

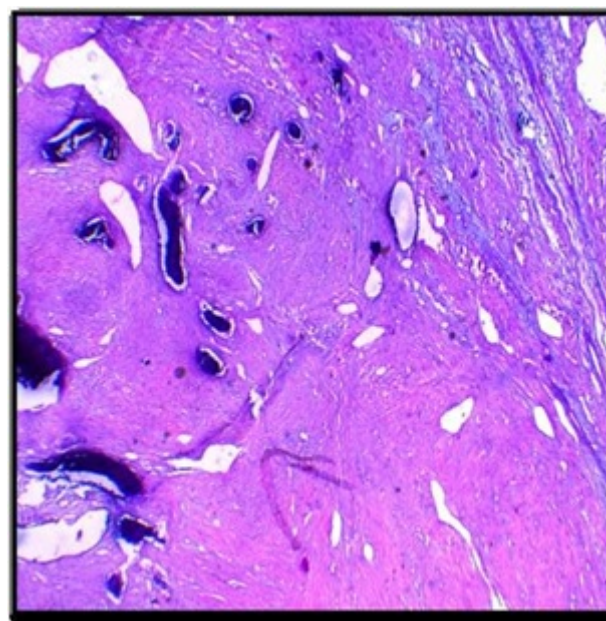


Figure 4: Central ossifying fibroma.

Discussion

Central ossifying fibroma is a rare, benign fibro-osseous lesion that occurs in the premolar and molar regions of the mandible in patients in the third and fourth decades. Females are more commonly affected and multiple lesions are often seen in black patients. The lesion reveals a painless course, very often only producing painless bone deformity [6,7]. Pindborg et al. defined the central ossifying fibroma as an encapsulated neoplasm containing fibrous tissue, metaplastic bone and mineralized masses with rounded borders and few entrapped cells [8]. Ossifying fibromas of the jaws generally manifests in second to fourth decades of life [6,7]; in our case, patient was 13 year old, which is similar with the juvenile (aggressive) ossifying fibroma (JOF) mainly affects individuals younger than 15 years of age [9], but behaves in an aggressive fashion when compared to ossifying fibroma. Bone swelling or expansion at the buccal and/or lingual cortical plates is the most frequent clinical sign of ossifying fibroma [10,11]. They are slow growing lesions and because of the slow growth, the cortical plates of the bone and the overlying mucosa or skin are invariably intact. They are generally asymptomatic until the growth produces a noticeable swelling and deformity. Small lesions are often discovered incidentally. Ossifying fibromas are usually solitary, but bilateral as well as multiple familial ossifying fibromas have also been reported [12,13]. Root divergence, displacement of teeth in the tooth bearing region or root resorption may be associated with the tumor [6,13]. In the present case, maxillary right permanent first molar was erupted but displaced buccally while the maxillary right permanent second premolar was still

unruptured and was displaced buccally as well as superiorly. The size of the lesion can range from 0.2-15 cm [14]; in our case the excised fibroma measured 3.5 3.2 1.6 cm. The most important radiographical feature of this lesion is well circumscribed and sharply defined border [15]. Mac Donald Jankowski [16] reported 64 cases of cement ossifying fibroma and found that were all well-defined unilocular, round or oval structures. Larger tumors may have a multilocular radiographical appearance. Mac Donald Jankowski [16] described three stages in the radiographic appearance. Initially the lesion is radiolucent (osteolytic image), which then becomes progressively radiopaque as the stroma mineralizes thus transforming in to mixed lesion. Eventually, the individual radiopacities coalesce to the extent that the mature lesion may appear sclerotic or radiopaque lesion. He also presented a summary of radiological features in 177 reported cases of cemento ossifying fibromas from the literature and his own files [14,16] demonstrating that 42% were radiolucent, 24% were radiopaque and 34% had mixed appearance. Three different patterns of radiographical borders were reported by Su et al. [14]: A defined lesion without a sclerotic border (40%), a well-defined lesion with a sclerotic border (45%), and a lesion with an ill-defined border (15%). Surgical curettage or enucleations are the initial treatment of choice for most small ossifying fibromas [17]. The circumscribed nature of the ossifying fibroma generally permits enucleation of the tumor with relative ease. Larger lesions that have destroyed considerable bone may necessitate surgical resection and bone grafting. The prognosis is very good, and recurrence after removal of the tumor is rarely encountered [6,15]. Liu [1] observed that the time of recurrence was always unpredictable, ranging from 6 months to 7 years after the operation. Therefore, there must be a long enough followup period of at least 10 years [1]. There is no evidence to suggest that ossifying fibroma ever undergo malignant change [6]. On the basis of age, site, clinical behaviour and radiographic findings, this lesion can also be termed as juvenile ossifying fibroma a variant of ossifying fibroma. It is seen in patients at a young age, the most common site of involvement is the maxilla, the clinical behaviour is rapid growth [18].

In the present case, the clinical features like age, gender, location of lesions and radiographic features are nearly similar to typical forms. The relationship between the occurrences of these three lesions is not obvious it could be coincidental. More case reports are needed to establish the relationship between them.

Conclusion

A case of COF in a 13-year old male patient who came with a swelling in right maxillary posterior region can be distinguished from the adult variant of ossifying fibroma on the basis of age, site and clinical behaviour, as well as radiographic and microscopic appearance. This case put forwards that a proper correlation of the clinical, radiological and the histological features is necessary for establishing a definitive diagnosis, as well as for categorizing the fibro

osseous lesions. Since chances of recurrence of COF are reported in the literature, surgical resection and follow-up of the patients is reasonable.

References

1. Liu Y, You M, Wang H, Yang Z, Miao J, et al. (2010) Ossifying fibromas of the jaw bone: a study of 20 cases. *Dentomaxillofacial Radiology* 39: 57-63.
2. Gondivkar SM, Gadbail AR, Chole R, Parikh RV, Balsaraf S (2011) Ossifying fibroma of the jaws: report of two cases and literature review. *Oral Oncol* 47: 804-809.
3. Sarwar HG, Jindal MK, Ahmad SS (2008) Cemento-ossifying fibroma-a rare case. *J Indian Soc Pedod Prev Dent* 26: 128-131.
4. Rangil JS, Silvestre FJ, Bernal JR (2011) Cemento-ossifying fibroma of the mandible: Presentation of a case and review of the literature. *J Clin Exp Dent* 3: e66-69.
5. Mac Donald-Jankowski DS (2009) Ossifying fibroma: a systematic review. *Dentomaxillofac Radiol* 38: 495-513.
6. Neville BW, Damm DD, Allen CM, Bouquot JE (2009) *Text Book of Oral and Maxillofacial Pathology* (3thedn), Philadelphia, PA: Sanders
7. Serra-Serra G, Berini-Aytés L, Gay-Escoda C (2009) Erupted odontomas: a report of three cases and review of the literature. *Med Oral Patol Oral Cir Bucal* 14:E299-303.
8. Pindborg JJ, Kramer IRH, Torloni H (1971) *Histological typing of odontogenic tumors, jaw cysts and allied lesions*. Geneva: World health Organization
9. Kramer IR, Pindborg JJ, Shear M (1992) (Histological typing of odontogenic tumours (2ndedn), Springer, Berlin, Germany.
10. Mintz S, Velez I (2007) Central ossifying fibroma: An analysis of 20 cases and review of the literature. *Quintessence Int.* 38: 221-227
11. ChiaChuan C, HsienYen H, Julia YC, ChuanHang Y, YiPing W, et al. (2008) Central ossifying fibroma: A clinicopathologic study of 28 cases. *J Formos Med Assoc* 107: 288-94
12. Sakoma T, Kawasaki T, Watanabe K (1998) concurrent cementifying and ossifying fibromas of the mandible. Report of a case. *J Oral Maxillofac Surg.* 56: 778-782.
13. Emin MC, Peruze C, Saadettin K, Alper A, Omer G (2004) Familial ossifying fibromas: Report of two cases. *J Oral Science.* 46: 61-64.
14. Su L, Weathers DR, Waldron CA (1997) Distinguishing features of focal cement osseous dysplasia and cement ossifying fibromas. II. A clinical and radiologic spectrum of 316 cases. *Oral Surg Oral Med Oral Pathol Oral Radiol Endod* 84: 540-9.
15. Regezzi JA, Sciubba JJ, Jordan RC (2009) Benign nonodontogenic tumors. *Oral Pathology, clinical pathological correlations* (5thedn), Elsevier, Noida 283-286.
16. Mac Donald Jankowski DS (1998) Cementoossifying fibromas in the jaws of Hong Kong Chinese. *Dentomaxillofac Radiol.* 27: 298-304.
17. Reichert PA, Philipensen HP (2004) Surrey: Quintessence; Ossifying fibroma. *Odontogenic tumor and allied lesions* 273-280.
18. Lohe VK, Degwekar SS, Bhowate RR, Kadu RP, Motwani MB (2011) Rapidly maturing juvenile ossifying fibroma: a case report. *Dentomaxillofacial Radiology* 40: 195-198.