

A Case of a 68 Year Old Male with Bilateral Giant Bullous Emphysema: A Case Report

Ben Victor Ubalde* and Rizalyn Piñera

Department of Internal Medicine, Fatima University Medical Center, Valenzuela, Philippines

Abstract

Background: Bullous disorder of the lung is primarily a medical problem. A bulla is an air-filled space of 1 cm in diameter within the lung which has developed because of emphysematous destruction of the lung parenchyma. Eighty percent of patients presenting with bullae have associated pulmonary emphysema, and this entity, therefore, is referred to as bullous emphysema. A bulla that takes up a third or more of the space in and around the affected lung is called a giant bulla. Because of its close association with emphysema, giant bullae are most often found in older patients who smoke or used to smoke. The primary management of Giant bullous emphysema is often surgical. In this case, management involves the use of a minimally invasive surgery or Video Assisted Thoracoscopic Surgery (VATS). However, with decreased clinical study outcome, management results to technical difficulties.

Objective: To present and provide information on the diagnosis, management and clinical outcome of a case with bilateral Giant bullous lung disease in a 68 year old male diagnosed with emphysema.

Case synopsis: A case of an asymptomatic, physically active male diagnosed with emphysema. Initially found to have right pneumothorax. He underwent Chest tube thoracotomy on his right chest. On CT scan, he was noted to have bilateral giant bullous emphysema. He underwent Video assisted thoracoscopic surgery, right bullectomy with upper lobe segmentectomy. During surgery, giant bullae of the left lung were left untouched. Post-operative course was uneventful. He was discharged in a stable condition.

Conclusion: Bullous emphysema may present with none to a severe distressing respiratory symptoms. In the event of sudden pleuritic chest pain with a history COPD, bullous emphysema should be a consideration. Avoidance of smoking prevents occurrence of COPD leading to bullous lung diseases.

Clinical recommendation: In conjunction with the decreased clinical study and absence of randomized control trial in the management and long outcome of treatment. Follow-up post discharge evaluation with accurate and adequate documentation is encouraged.

Keywords: Bullous disorder • Video assisted thoracoscopic surgery • Lungs • Chronic obstructive pulmonary disease • Bullous emphysema

Introduction

Chronic Obstructive Pulmonary Disease (COPD) is characterized by a largely irreversible obstruction of the airways, and encompasses both emphysema and chronic bronchitis. The incidence of COPD was higher in men than in women (with a relative risk (RR) of 1.5-fold higher in men). The incidence increased almost 10-fold from 0.78/1000PY at age 40–44 to 6.82/1000PY at age 75–79 (Figure 1). The incidence rate of COPD was much higher in smokers compared to non-smokers and this for all age categories and in both sexes (Figure 2). Smoking is still considered a major risk factor in COPD [1-3].

The pathophysiology of bullous emphysema is intimately related to the chronic inflammation of the distal airspaces mostly secondary to insult, i.e., cigarette smoke, which results in a breakdown of the alveolar walls which subsequently leads to permanent enlargement of airspaces. Bullous emphysema affects greater than five percent of the population with the worldwide prevalence being almost 12 percent in adults over the age of 30. It

is also ranked third in causes of death in the United States and kills more than 120,000 individuals a year [1].

In a study made by Krishnamohan P, et al. [4], the incidence of giant bullae is considered uncommon. Bullous lung disorder being primarily a medical problem requires prompt medical management. Though small bulla can be treated medically, most case of bullous emphysema is treated with surgical bullectomy [5].

Case Synopsis

This is a case of an active 68 year old male diagnosed with emphysema. He presents on Emergency Department (ED) with a complaint of dyspnea which started 7 days prior to admission. He had an accident causing his right arm to overstretch. Subsequently, he experienced sudden sharp pain on his right chest accompanied with dyspnea and shortness of breath. He took his maintenance medication of Seretide 2 puffs which provided temporary relief. Unable to lie flat, he continues to sleep in a sitting position for almost a week. As time progresses, he complained of exertional dyspnea and worsening shortness of breath. No consult was done and no medications taken, Interim showed persistence of symptom.

Three days prior to admission, shortness of breath and dyspnea became more apparent. This time, he started using oxygen support at 2 liters per minute via nasal cannula which provided temporary relief.

Few hours prior to admission, he noted worsening of symptoms not relieved with oxygen support. Difficulty of breathing, exertional dyspnea and easy fatigability were increasing in severity. Hence consult was done.

*Address for Correspondence: Ben Victor Ubalde, Department of Internal Medicine, Fatima University Medical Center, Valenzuela, Philippines, Tel: +639053074167, E-mail: benvictoru@gmail.com

Copyright: © 2021 Ubalde BV, et al. This is an open-access article distributed under the terms of the creative commons attribution license which permits unrestricted use, distribution and reproduction in any medium, provided the original author and source are credited.

Received 09 October, 2021; **Accepted** 19 November, 2021; **Published** 26 November, 2021

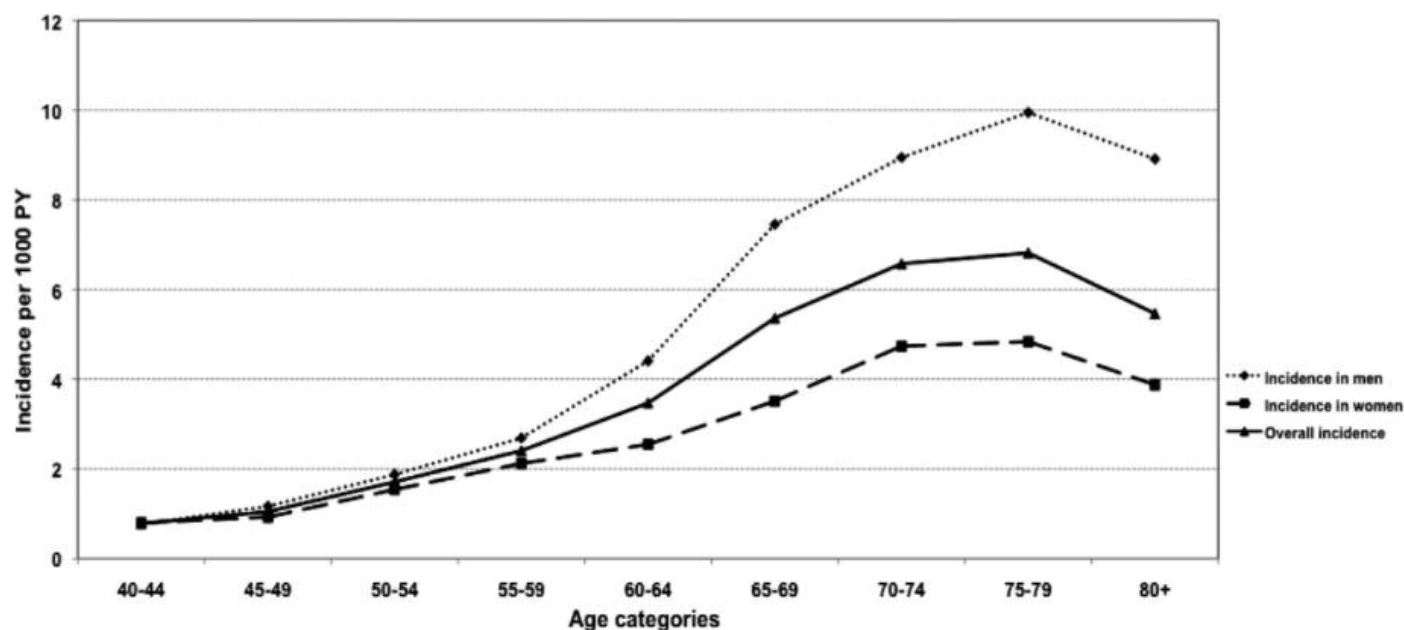


Figure 1. Age and gender-specific incidence rates of physician-diagnosed COPD (/1000PY).

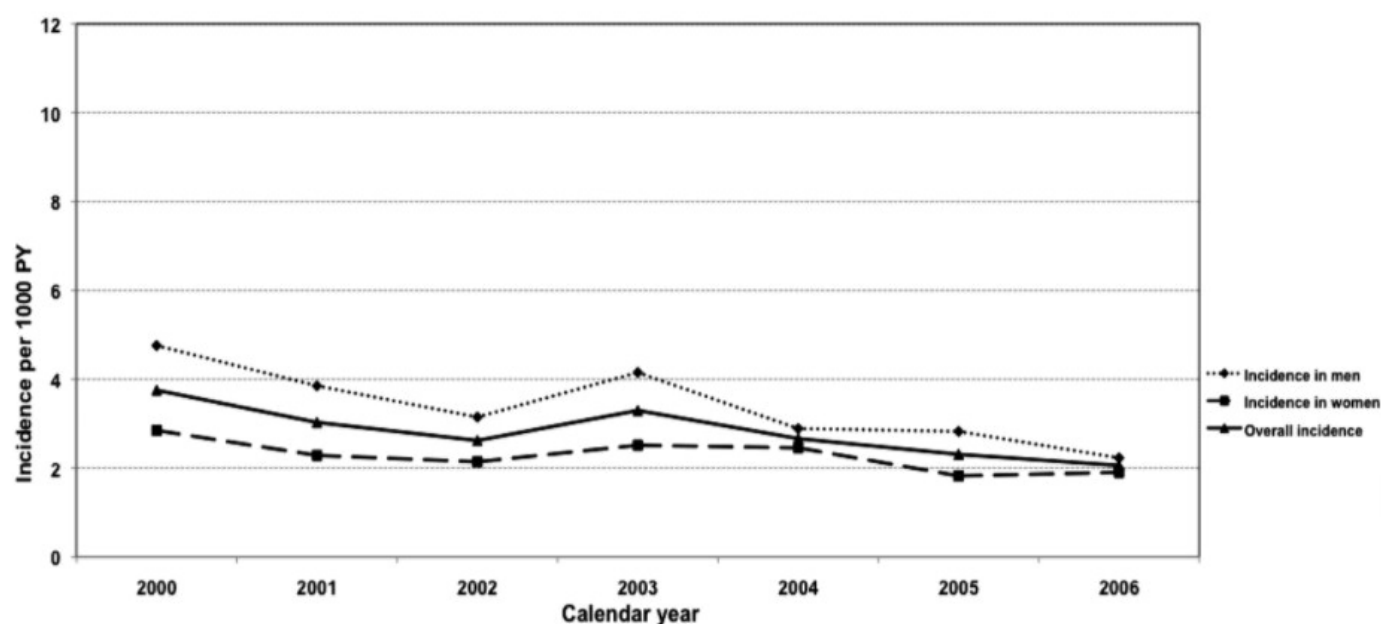


Figure 2. Weighted (3 year mean) calendar year-specific incidence of COPD (bottom).

On ED, he appeared to be anxious and in respiratory distress. Vitals signs showed hypertension with blood pressure of 150/90, tachycardic at heart rate of 95, tachypneic with respiratory rate of

Oxygen saturation was 90%. He has a normal BMI, height of 163 cm and weight of 65 kg with a BMI of 24.5. On physical findings revealed decreased breath sounds on both lung fields accompanied with occasional wheezes. Adynamic precordium, heart rate was tachycardic with regular and rhythm. Rest of examination findings were unremarkable.

He was started on oxygen support at 10 liters per minute via face mask. Blood works and imaging were done. Initial chest x-ray showed Right Pneumothorax (Figure 3). Afterwards, he underwent right chest tube thoracotomy. Chest imaging of post chest tube insertion showed re-expansion of the right lung (Figure 4).

On assessment, constant babbling was noted and high resolution CT scan was ordered. On CT, there was presence of multiple bullae and bleb formations

on both upper hemithoraces. Largest bulla measuring on the right 11.4 × 5.1 × 13 cm and largest on the left 11 × 6 × 15.8 cm; minimal pneumothorax, extensive subcutaneous emphysema, reticular and ground-glass opacities in the right lung probably pneumonia (Figure 5).

Interpretation of arterial blood gas revealed partially compensated respiratory acidosis with saturation 90%. Complete blood count was done showing Hgb of 159, HCT 0.503, with an increased WBC of 13.63 and PLT 220.

Intravenous antibiotic with Piperacillin Tazobactam 2.25 G was started together with oral azithromycin 500 mg/tab for 3 days. He was placed on Aminophylline drip, Ipratropium plus salbutamol nebulization every 8 hours and steroids. He was admitted in the Intensive care unit and was hooked to oxygen support. Subsequently, referred to surgery for co-management and was advised to undergo VATS bullectomy.

He underwent VATS (VideoAssisted Thoracic Surgery) with segmentectomy

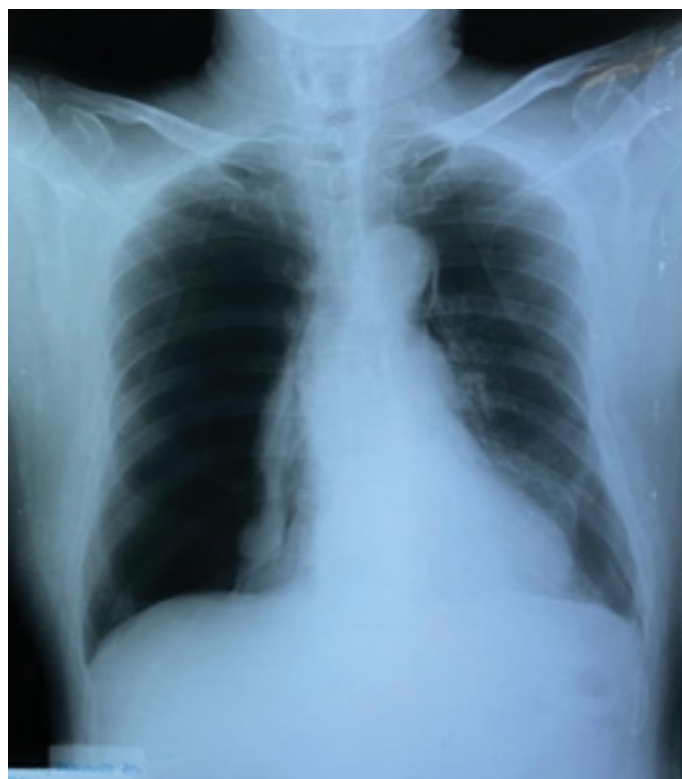

Figure 3. Hyperlucency with no pulmonary vascular markings (right lung), massive pneumothorax.

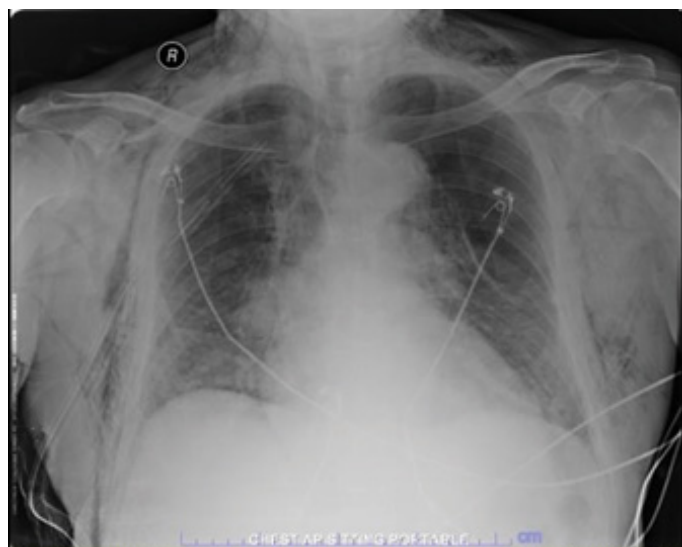

Figure 4. Right lung re-expansion, post chest tube thoracotomy.

of right upper lobe under general anesthesia. On thoracoscopy, a large bullae is seen on the right lung occupying almost half of the right upper lobe (Figure 6). Incision was made at the 3rd ICS, mini thoracotomy on anterior axillary area. Identification and isolation of bullae formations was done. This was followed with resection of the bullae and segment of the right upper lobe (Figure 7). After resection, checking of air leaks was done. Nevertheless, remaining lung segments were adequately expanding. On the opposite side, left lung remain untouched with giant bullae intact.

He was received from Operating Room with CTT on right chest together with a JP drain. He was placed on continuous vital signs monitoring. Post-op course was uneventful. He continued to improve without difficulty.

He was started on incentive spirometry with 10 cycles at 2-4 hours. He underwent 6 minutes' walk test successfully without episodes of dyspnea and shortness of breath. A distance of >200 meters was reached. Vital signs

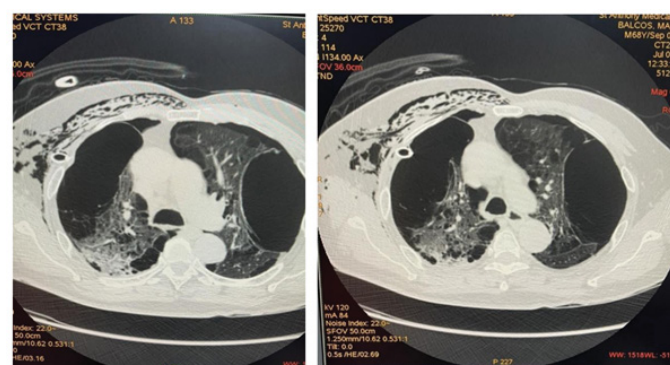


Figure 5. HRCT: Multiple bullae and bleb formations, both upper hemithoraces. Centrilobular and paraseptal emphysematous changes, bilateral. Minimal pneumothorax, bilateral, more pronounced on the left. Extensive subcutaneous emphysema, both anterior and right lateral chest walls as well as in the right axillary, right upper arm and right lower cervical regions. Reticular and ground-glass opacities in the right lung are likely due to an infectious/inflammatory process (e.g. pneumonia). Prominent and enlarged mediastinal lymph nodes. Atherosclerotic aorta and coronary arteries. Osteodegenerative changes of the spine. Hepatic steatosis.

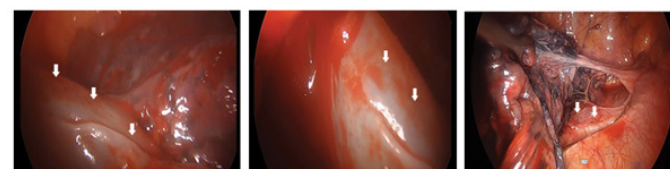


Figure 6. Photo during video assisted thoracoscopic surgery (white arrow showing large bullae in the right lung).

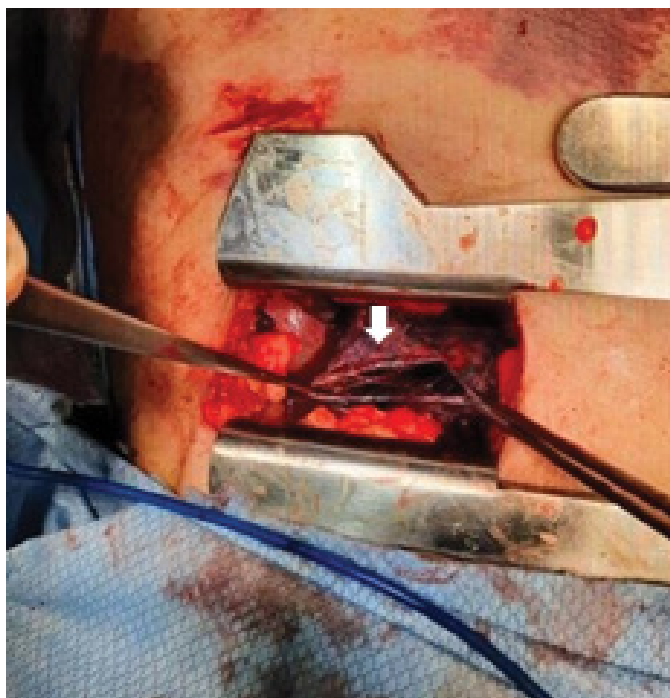

Figure 7. Incision at the 3rd ICS mini-thoracotomy anterior axillary area, followed with clamping of bullae and apical segment of upper lobe, then resection of the bullae and right upper lobe segmentectomy (white arrow: bulla).

were taken before and after the test which showed normal limits. He was then discharged in a stable condition with a JP drain in place.

Discussion

Bulla by definition is an air-filled space measuring more than 1 cm in diameter and is made up of a fibrotic wall coming from an alveolar septae.

Despite the high prevalence of this disorder, the exact role of bullae on pathogenesis of pneumothorax is still a challenge. Lung bulla is categorized to two main groups: bullae within otherwise a normal lung parenchyma which is usually single and bullous formation within emphysematous lung which is usually multiple [6].

One major risk factor for occurrence of lung bullous disorder is Smoking. Our patient with a significant smoking history of 30 pack years places him at high risk in developing COPD conditions and later on bullous lung disease. Most patients with bullae have a significant cigarette smoking history, although cocaine smoking, pulmonary sarcoidosis, 1-antitrypsin deficiency, 1-antichymotrypsin deficiency, Marfan's syndrome, Ehlers-Danlos syndrome and inhaled fiberglass exposure have been shown to be associated with emphysematous lung bullae as well [7]. Luser evaluated the relationship between smoking and bulla in idiopathic spontaneous pneumothorax in case-control study. Their finding revealed that all their patients were smoker.

Although diagnosed with COPD, he had been living an active lifestyle, with no apparent signs and symptoms with his activities of daily living. Bullous emphysema may be asymptomatic. The diagnosis is being made in the course of routine chest radiography; complain of progressive dyspnea or chest pain over several months due to the gradual increase in the size of the bullae, though they may occasionally regress spontaneously. They may develop sudden severe breathlessness due to the development of a spontaneous pneumothorax or sudden increase in size of the bulla due to air trapping [8].

Apart from having a thorough history and a good physical examination, imaging modalities offers a good guide in the management of the disorder. Chest X-rays are commonly prescribed in cases of dyspnea and respiratory complaints. In our case, he presents with 1 week history of DOB prompting the need for x-ray. Initial Chest radiogram showed hyperlucency devoid of lung markings suggestive of right pneumothorax. Blood tests like hemoglobin and hematocrit are needed to rule out anemia as contributory to dyspnea and evaluate secondary Polycythemia brought about by chronic hypoxemia [9]. Arterial blood gases are necessary for severe respiratory impairment and those candidates for surgery as well. However to determine the exact size, chest Computed Topography (CT) is required to demonstrate detailed characterization of the size, number and location of bullae. CT is a sensitive tool which reveals the exact anatomic location of the bullae a feature which might be easily missed in AP or lateral view of chest X-ray [10]. In this case, multiple bullae and bleb formations of both upper hemithoraces were noted. Moreover, bilateral centrilobular and paraseptal emphysematous with bilateral minimal pneumothoraxes were seen.

Due to sudden respiratory compromise, bullous emphysematous patient may benefit from conservative management, which includes appropriate combination of inhaled glucocorticoid, long acting beta agonist and long acting anticholinergic agent. As such, to alleviate symptoms it he was started with Hydrocortisone 50 mg IV every 6 hours, Doxofylline 400 mg/tab OD, Ipratropium Salbutamol nebulization every 8 hours and Indacaterol plus Glycopyrronium 1puff once a day. Intravenous antibiotics was started as well. However, Bullectomy is generally considered the treatment of choice to avoid the potential risk of future pneumothorax, reexpand healthy areas of collapsed parenchyma, improve the respiratory dynamics, and, consequently, improve the quality of life in these patients [11].

On a study of Ruan SY et al. [11], indications of surgical bullectomy of COPD-related bullae includes:

1. Severe functional limitation despite maximal medical therapy
2. The bulla's occupying more than one third of the hemithorax (more ideal if the bulla occupies more than 50% of the hemithorax),
3. No advanced emphysema in the non-bullous adjacent lung, and
4. No important comorbidities

On the other hand, Martinez FJ, et al. [8] presents more common indications for bullectomy, which includes:

1. Severe dyspnea due to giant bullae (occupying approximately 30% or more of hemithorax) that is refractory to medications and pulmonary rehabilitation

2. Spontaneous secondary pneumothorax

3. Mediastinal shift and or herniation due to giant bulla. The formation of giant bullous emphysema is a good indication of surgical management.

Contraindications to bullectomy includes: ongoing cigarette smoking, significant comorbid disease, poorly defined bulla on chest imaging, pulmonary hypertension and comorbid conditions such as heart failure. As per Martinez FJ et al. [8], contraindications for bullectomy came from case series and experience with lung volume reduction since no RTC for bullectomy have been performed.

The presence of single giant bullae affects respiration. Moreover, the occurrence of bilateral giant bullae compromises lung function, much more complicate intervention. Bilateral bullae can be managed by single stage or 2 stage approach. In a study done by Endou M, et al. [12], bilateral bullae can be surgically treated by a two-stage operation. On the other hand, the one step approach involves longer and greater surgical invasion. This technique minimized decreased oxygenation due to re-expansion pulmonary edema [13]. Thus, post-operatively complications tend to be less.

The team performed VATS (Video Assisted Thoracoscopic Surgery) together with bullectomy and right upper lobe segmentectomy secondary to persistent air leakage. Video-assisted thoracic surgery (VATS) is, at present, the minimally invasive surgical technique of choice for the treatment of spontaneous recurrent or persistent pneumothorax. VATS has progressively replaced open thoracotomies in most thoracic surgery centers around the world because of its safety profile in elderly patients, better pain control, faster recovery times, and easier control of bleeding [12]. Post-operative course was unremarkable. No untoward signs and symptoms were noted. Consequently, CTT was removed on post-operative day 4.

Prior to discharge, incentive spirometry was utilized 10 cycles every 2–3 hours. Six minute walk test was done to assess and evaluate treatment outcome and functional capacity. There are several ways to assess or evaluate functional exercise capacity. The modality used should be chosen based on the clinical question to be addressed and on available resources. The most popular clinical exercise tests in order of increasing complexity are stair climbing, a 6 minute walk test, a shuttle- walk test, detection of exercise-induced asthma, a cardiac stress test (e.g., Bruce protocol), and a cardiopulmonary exercise test [14]. The 6-min walk (6MW) test is commonly used to assess exercise capacity in patients with COPD and to track functional change resulting from disease progression or therapeutic intervention [15]. The total distance walked is recorded as the 6 minute walk distance (6MWD). The distance walked in 6 min (6MWD) is frequently used as an outcome measure in evaluating the benefit of pulmonary rehabilitation [16].

In A review conducted by Celli [17], investigating predictors of mortality in COPD, stated that exercise capacity is the most important predictor of survival. Moreover, Pinto-Plata VM, et al. [18], showed that 6MWD was able to predict survival in COPD patients and that patients unable to walk >100 m had an extremely high mortality (92%) at one year. In this case, he was able to perform >150 meters 6MWD.

Conclusion

All in all, Bullous emphysema should be consideration individuals with history of COPD presenting with sudden chest pain. Like other diseases, we can prevent COPD and lessen bullous formation thru smoking cessation and avoidance. The 6 minute walk test is a good and cost effective diagnostic tool in assessing functional capacity as well as a good predictor of mortality in patient with post-operative lung conditions.

Clinical Recommendation

In conjunction with the decreased clinical study and absence of randomized control trial in the management and long outcome of treatment. Follow-up post discharge evaluation with accurate and adequate documentation is encouraged.

References

1. Siddiqui, Najam A, Mohamed K. Mansour, and Vinod Nookala. "Bullous emphysema." *StatPearls* [Internet]. (2020).
2. University of Rochester Medical Center Rochester, NY, Giant Bullae, Health Encyclopedia. (2021).
3. Afonso, Ana SM, Katia MC Verhamme, Miriam CJM Sturkenboom, and Guy GO Brusselle. "COPD in the general population: Prevalence, incidence and survival." *Respir Med* 105 (2011): 1872-1884.
4. Desai, Parag, and Robert Steiner. "Images in COPD: Giant bullous emphysema." *Chronic Obstr Pulm Dis* 3 (2016): 698.
5. Krishnamohan, Pradheep, K. Robert Shen, and Dennis A. Wigle, et al. "Bullectomy for symptomatic or complicated giant lung bullae." *Ann Thorac Surg* 97 (2014): 425-431.
6. Wheatley III, Grayson H, and Aaron S. Estrera. "Bullous lung disease." CTS NET: The Cardiothoracic Surgery Network (2010).
7. Shah, NN, R. Bhargava, Z. Ahmed, and DK. Pandey, et al. "Unilateral bullous emphysema of lung." *Lung India* 24 (2007): 30.
8. Martinez, Fernando J, and Kathryn A. Collins. "Bullectomy for giant bullae." (2021).
9. Aghajanzadeh, Manouchehr, L. Pourmehr, MR. Asgary, and AA. Fomani, et al. "An investigation into symptoms, diagnosis, management, and complications of treatment in patients with pulmonary bullae." *JSM Clin Cytol Pathol* 4;5 (2019).
10. Mineo, Tommaso Claudio, Vincenzo Ambroggi, and Eugenio Pompeo, et al. "New simple classification for operated bullous emphysema." *J Thorac Cardiovasc Surg* 134;6 (2007): 1491-1497.
11. Ruan, Sheng-Yuan, Chun-Ta Huang, and Jung-Yien Chien, et al. "Non-surgical management of giant lung bullae during mechanical ventilation." *Respir care* 56 (2011): 1614-1616.
12. Endou, Masato, Ayumi Yasuhira, Kelko Nishiyama, and Mitsuharu Kodaka, et al. "Peri-operative management of a patient with bilateral giant bullae and pneumothorax in the context of severe pulmonary obstructive disease." *J Anesthe Clinic Res* 2, no. 162 (2011): 2.
13. Mehrotra, Mayank, Jason R. D'Cruz, and Mary E. Arthur. "Video-assisted thoracoscopy." (2018).
14. ATS Committee on Proficiency Standards for Clinical Pulmonary Function Laboratories. "ATS statement: guidelines for the six-minute walk test." *Am J Respir Crit Care Med* 166 (2002): 111-117.
15. Carter, Rick, David B. Holiday, Chiagozie Nwasuruba, and James Stocks, et al. "6-minute walk work for assessment of functional capacity in patients with COPD." *Chest* 123, no. 5 (2003): 1408-1415.
16. Polkey, Michael I, Martijn A. Spruit, Lisa D. Edwards, and Michael L. Watkins, et al. "Six-minute-walk test in chronic obstructive pulmonary disease: Minimal clinically important difference for death or hospitalization." *Am J Respir Crit Care Med* 187, no. 4 (2013): 382-386.
17. Celli, Bartolome R. "Predictors of mortality in COPD." *Respir Med* 104, no. 6 (2010): 773-779.
18. Pinto-Plata, VM, C. Cote, H. Cabral, and J. Taylor, et al. "The 6-min walk distance: Change over time and value as a predictor of survival in severe COPD." *Eur Respir J* 23 (2004): 28-33.

How to cite this article: Ubalde, Ben Victor and Rizalyn Piñera. "A Case of a 68 Year Old Male with Bilateral Giant Bullous Emphysema: A Case Report." *J Pulm Respir Med* 11(2021)". *J Pulm Respir Med* 11 (2021): 572.