

Pericarditis Post Pacemaker Implantation Progressing To Cardiac Tamponade after Treatment of an Incidental Pulmonary Embolism

Ahmad A. Alwassia*, Bhanu Patibandla, Anthony Bartley, Vinod Chaubey, Ramses M Thabet, Arvind Gireesh and Nitya Sthalekar

Department of Internal Medicine, Saint Vincent Hospital Worcester, USA

Abstract

This report presents a case of cardiac tamponade that developed after a patient who presented with a pleuritic chest pain 2 weeks after pacemaker implantation. The patient developed cardiac tamponade after being treated with heparin drip for an incidental pulmonary embolism.

Keywords: Pericarditis; Pacemaker; Cardiac tamponade

Introduction

Pericarditis post Pacemaker Implantation (PMI) was first reported in 1975. Levy et al. reported that pericarditis was observed in about 2% of patients undergoing PMI [1]. However, Greene reported a high incidence of 4.9% [2]. Perforation PMI may occur when the tip of a passive fixation lead or the screw of an active fixation lead reaches the pericardial cavity [3]. In a previous report of 111 postmortem examinations of patients implanted with a pacemaker, perforation of the RA was demonstrated in 27% of cases [4]. The following report presents a case of pericarditis post PMI; the patient later developed cardiac tamponade after being treated with anticoagulation for an incidental pulmonary embolism.

Case Report

Our patient is a 79-year-old male with a medical history of hypertension, hyperlipidemia, and longstanding history of bradycardia and bifascicular block who underwent dual-chamber pacemaker implantation 2 weeks prior to presenting with acute onset of sharp substernal chest pain radiating towards left side of the chest. The pain was associated with dyspnea and aggravated by deep breathing. He was taking low dose aspirin on daily basis. His family history is notable for factor V leiden mutation in his son. On examination, the patient was afebrile; Blood pressure was 120/62, heart rate of 60, respiratory rate of 15, and an oxygen saturation of 97% on room air. He appeared comfortable and was speaking in full sentences. His cardiopulmonary exam was unremarkable. His EKG was difficult to interpret given the ventricular paced rhythm; however no new ST, PR or T wave changes were noted. His initial laboratory data showed a WBC of $12 \times 1000/\mu\text{l}$, an ESR of 31 mm/hr, and Troponin T was 0.035 ng/ml (normal < 0.03). The basic metabolic panel including BUN and creatinine were within normal limits. A Computed Tomography (CT) of the chest with intravenous contrast performed while the patient was in the emergency department demonstrated small segmental and sub segmental pulmonary emboli in the left upper lobe. A heparin drip (infusion) was initiated in emergency department as it was thought that the Pulmonary Embolism (PE) was the cause of the patient chest pain. Echocardiogram done at the time of admission to the medical floor showed a small pericardial effusion with no evidence of tamponade; ejection fraction was 65%. Venous duplex of the lower extremities did not reveal any evidence of Deep Vein Thrombosis (DVT). The patient did not have a prior history of deep vein thrombosis or pulmonary embolism. The following day, on the medical floor, he became hypotensive with a systolic blood pressure around 70s to 80s with worsening chest pain, dyspnea, nausea, and vomiting. On exam, he appeared to be in significant distress with

Beck's triad of hypotension, decreased heart sounds, and significant Jugular Venous Distention (JVD). A positive Kussmaul sign and pulsus paradoxus were present. A repeat echocardiogram at that time showed a significant pericardial effusion with a 2cm clear space anterior to the right ventricle in the sub costal view and diastolic collapse of the right ventricle suggestive of tamponade (Figure 1). The Heparin drip was discontinued and he was taken to the cardiac catheterization lab for an

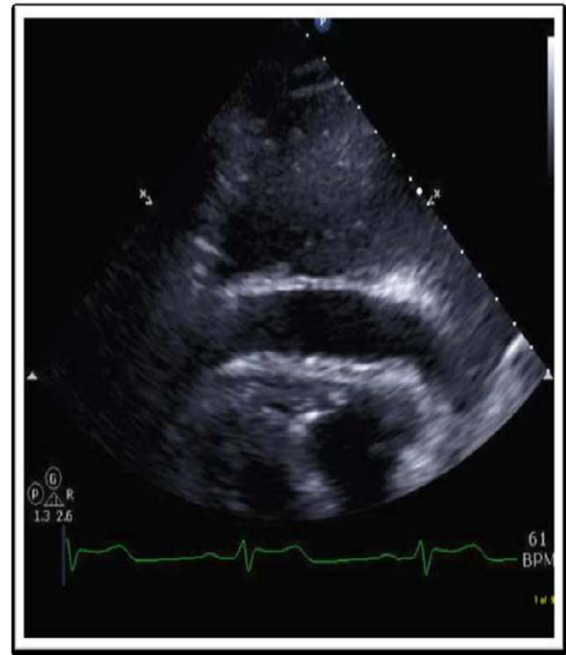


Figure 1: Transthoracic echocardiogram: A large pericardial effusion is clearly evident in this image.

*Corresponding author: Ahmad Alwassia, Department of Internal Medicine, Saint Vincent Hospital, USA, 123 Summer st, Worcester, MA 01608, USA, Tel: 508-363-5000; Fax: 508-363-9547; E-mail: alwassia5@gmail.com

Received July 26, 2013; Accepted August 08, 2013; Published August 15, 2013

Citation: Alwassia AA, Patibandla B, Bartley A, Chaubey V, Thabet RM, et al. (2013) Pericarditis Post Pacemaker Implantation Progressing To Cardiac Tamponade after Treatment of an Incidental Pulmonary Embolism. J Cardiovasc Dis Diagn 1: 119. doi:10.4172/2329-9517.1000119

Copyright: © 2013 Alwassia AA, et al. This is an open-access article distributed under the terms of the Creative Commons Attribution License, which permits unrestricted use, distribution, and reproduction in any medium, provided the original author and source are credited.

emergent pericardiocentesis. Right heart catheterization showed a near equalization of the right atrial; right ventricular diastolic, pulmonary arterial diastolic, and pulmonary capillary wedges pressures. Pericardiocentesis drained about 800 mL of bloody fluid; a Jackson-Pratt (JP) drain was left in place. He became hemodynamically stable post procedure and transferred to CCU for further care. Pericardial fluid analysis showed too numerous RBC to count, WBC 28,160 cells/ul, and total protein of 5.8 g/dl. A significant amount of serosanguinous fluid drained from the JP drain over the following 48 hours. The patient was started on Ibuprofen 600 mg TID for pericarditis. His chest pain and dyspnea continued to improve and on the day of discharge the patient was chest pain free. With regards to the pulmonary embolism, we considered that it was most likely chronic and an incidental finding. Anticoagulation was not immediately initiated due to concern of worsening the patient's hemopericardium. It was agreed, however, that he would require long-term anticoagulation to prevent potential future episodes of PE.

Discussion

The patient in this case likely had acute pericarditis on presentation. Given the pleuritic nature of the pain associated with pericarditis, a pulmonary embolus was a diagnostic possibility, although, the patient was not tachycardic or hypoxic on presentation. In retrospect, the patient did have an elevated WBC count, a small pericardial effusion, and a mildly elevated ESR on presentation, which could be consistent with acute pericarditis. His EKG unfortunately was difficult to interpret given the paced rhythm, and the mild troponin elevated was of unclear etiology. The patient had a normal nuclear stress test 2 month prior to presentation and his symptoms were atypical of angina. The finding of a PE in the left upper lobe of the lung in the initial CT added to the diagnostic dilemma. After speaking with the radiologist the following day, it was felt that the PE was likely an incidental and chronic finding. The patient developed cardiac tamponade after anticoagulation was started for the treatment of the PE since it was presumed to be the cause of the patient's chest pain when he presented to the emergency room. Den Exter et al. showed in their study that most physicians decided to treat a patient with an incidental PE [5]. However, it is difficult to determine the need for anticoagulant treatment in patients with an

incidental sub-segmental PE, particularly in the absence of cancer and a DVT as in our case. In their study, the majority of physicians opted to manage patients with a small, asymptomatic incidental PE on an outpatient basis. However, further studies are needed to clarify the risk-benefit ratio of anticoagulant therapy in an incidental PE, especially with regards to safety of withholding treatment in patients with an incidental sub segmental PE. A number of mechanisms could account for the patient's presentation. There might have been micro perforation of the RA active fixation lead post PMI that resulted in acute inflammation and the echocardiogram did show a small pericardial effusion on presentation. The small effusion on admission may have solely been the result of inflammation; however there might have been a small amount of blood oozing into the pericardium as well. After initiation of anticoagulation, severe intra pericardial bleeding and cardiac tamponade ensued.

Conclusion

Pericarditis and cardiac perforation can occur post PMI. It is important to consider these complications before starting anticoagulation for any reason, especially if PMI was performed recently. Weighing the risks, benefits, and timing of anticoagulation after PMI is critical as demonstrated by this case.

References

1. Levy Y, Shovman O, Granit C, Luria D, Gurevitz O, et al. (2004) Pericarditis following permanent pacemaker insertion. *Isr Med Assoc J* 2004 6: 599-602.
2. Greene T, Portnow A, Huang S (1994) Acute pericarditis resulting from an endocardial active fixation screw-in atrial lead. *Pacing Clin Electrophysiol* 17: 21-25.
3. Sivakumaran S, Irvin M, Gulamhusein S, Senaratne M (2002) Post pacemaker implant pericarditis: Incidence and outcomes with active fixation leads. *Pacing Clin Electrophysiol* 25: 833-837.
4. Ishikawa K, Cida K, Taniguchi T (1999) Myocardial perforation and/or penetration by an endocardial electrode of the permanent pacemaker in autopsy cases. *J Arrhythmia*; 15: 29-44.
5. Den Exter PL, Van Roosmalen MJ, Van den Hoven P, Klok FA, Monreal M, et al. (2013) Management approach to an incidental pulmonary embolism: an international survey. *J Thromb Haemost* 11: 208-213.