

Resection of the Falciform Ligament and Ligamentum Teres Hepatis in Cytoreductive Surgery and Hyperthermic Intraperitoneal Chemotherapy (HIPEC)

Thejus Thayil Jayakrishnan¹, Avishkar Sharma¹, Anthony J Zacharias¹, Paul M Knechtges², Sam George Pappas³, Fabian M Johnston¹, T Clark Gamblin¹ and Kiran K Turaga^{1*}

¹Division of Surgical Oncology, Department of Surgery, Medical College of Wisconsin, Milwaukee, WI, USA

²Division of Diagnostic Radiology, Department of Radiology, Medical College of Wisconsin, Milwaukee, WI, USA

³Division of Surgical Oncology, Department of Surgery, Loyola University Medical Center; Maywood, IL, USA

Abstract

Background: Routine resection of falciform ligament and ligamentum teres hepatis (FL-LTH) during cytoreductive surgery and hyperthermic intraperitoneal chemotherapy (CRS+HIPEC) has been advocated but may be associated with increased complications. We aimed to study the role of FL-LTH resection at the time of CRS+HIPEC.

Methods: Retrospective review of patients who underwent CRS+HIPEC from January, 2010 to April, 2013 was conducted. Non-parametric methods were used for analyses.

Results: CRS+HIPEC was performed in 71 patients (FL-LTH resection in 57, 80.2%). The sensitivity and specificity of visual examination were calculated as 97.4% and 75.0%, respectively. Visual examination falsely classified 1/33 cases as disease free (3.0% False-negative, pathology showed carcinomatosis) and 6/24 as diseased (25% False-positive, pathology showed fibroadipose tissue). False-positive resection was not associated with increased complications (0/6). The recurrence in porta-hepatis (of n=48 with CC0 cytoreduction) was lower in the resected group (3/41, 7.3%) vs. non-resected (2/7, 28.6%), and associated with a hazard-ratio of 0.17 (95% CI 0.02 – 1.20, p-value 0.07) at a median 11 (IQR 7.0 – 16.7) months follow-up.

Conclusions: Visual examination during CRS+HIPEC may miss disease at the falciform ligament. A policy of routine resection is not associated with increased complications and should be considered.

Keywords: Peritoneal neoplasms; Liver anatomy; Porta hepatis; Liver surgery

Introduction

Cytoreductive Surgery and Hyperthermic Intraperitoneal Chemotherapy (CRS+ HIPEC) is an evolving paradigm in the treatment of cancer disseminated into the peritoneum [1,2]. While the therapeutic role of CRS+HIPEC has been well established through multiple studies, efforts are ongoing to improve the surgical techniques such as the use of minimally invasive approach for patient selection [3-6]. A common site of disease recurrence resulting in treatment failure in these patients is the perihepatic region and porta hepatis [7,8]. This could potentially be attributed to the complex anatomy of the liver surface with its fissures and ligaments that may result in inadequate visualization of disease and incomplete cytoreduction [8]. Falciform ligament and ligamentum teres hepatis (FL-LTH) are remnants of the ventral mesentery and fetal umbilical vein respectively, and connect the anterior surface of the liver to the anterior abdominal wall. The ligament may serve as a potential nidus for occult disease resulting in recurrence. Even though routine resection of FL-LTH has been proposed to avoid the possibility of any missed disease, [8] in clinical practice, it is often performed based on the visual examination for disease that may not be reliable.

The current study aimed to examine the correlation of visual findings of a surgeon with the pathological findings of resected specimens of FL-LTH, and to evaluate the impact of FL-LTH resection during CRS+HIPEC on the oncological outcomes in terms of recurrence of disease at porta hepatis.

Methods

Retrospective review of patients that underwent CRS+HIPEC for

peritoneal carcinomatosis between January, 2010 and April, 2013 was performed after approval by the Institutional Review Board (IRB). Patients who underwent more than one cytoreductive surgery and those who underwent CRS at an outside center were excluded. Data on tumor characteristics, operative details, hospital course and morbidity, recurrence and survival outcomes were extracted and entered into a pre-specified data extraction sheet. Length of hospital stay was calculated from the date of surgical procedure to the date of discharge and survival was calculated from the date CRS+HIPEC. All patients being evaluated for CRS+HIPEC undergo cross sectional imaging with contrast enhanced CT scans, diffusion weighted MRI with a 1.5 or 3 Tesla coil and a PET/CT fusion scan based on the histology being evaluated. Patients with extensive disease (PCI score >11 for gastric cancer, and >19 for colorectal and non-gastric primaries) are usually excluded from CRS+HIPEC.

*Corresponding author: Kiran K Turaga, MD, MPH, 9200 W Wisconsin Ave, Milwaukee, WI 53226, USA, Tel: 414-805-5078; Fax: 414-805-5771; E-mail: kturaga@mcw.edu

Received September 01, 2014; Accepted September 23, 2014; Published September 30, 2014

Citation: Jayakrishnan TT, Sharma A, Zacharias AJ, Knechtges PM, Pappas SG. Resection of the Falciform Ligament and Ligamentum Teres Hepatis in Cytoreductive Surgery and Hyperthermic Intraperitoneal Chemotherapy (HIPEC). Journal of Surgery [Jurnalul de chirurgie] 2014; 10(2): 131-134 DOI: [10.7438/1584-9341-10-2-5](https://doi.org/10.7438/1584-9341-10-2-5)

Copyright: © 2014 Naidu K, et al. This is an open-access article distributed under the terms of the Creative Commons Attribution License, which permits unrestricted use, distribution, and reproduction in any medium, provided the original author and source are credited.

Technique of falciform ligament resection at the time of cytoreductive surgery

CRS is undertaken after adequate pre-operative preparation and appropriate placement of central venous catheters. A diagnostic laparoscopy is usually performed for high grade histology to allow staging through the left upper quadrant optical trocar. Upon performing a laparotomy, the anterior peritoneum is stripped away from the midline and a window is created in the peritoneum to examine the surfaces. The anterior peritoneum is stripped with the falciform ligament from the umbilicus all the way up to the investing peritoneum over the inferior vena cava, and then stripped off the surface of the liver until it becomes contiguous with the LTH. The pont hepatic is divided to allow for complete resection of the LTH as it inserts into the left portal vein.

Complete cytoreduction is performed using the techniques described by Sugarbaker and others. HIPEC is performed using the closed technique [9].

Follow up

The first post-operative imaging study is usually performed at 6 weeks. Subsequent visits were planned as 3 monthly visits for 2 years and 6 monthly visits for next 3 years and less frequently for low grade histology. All image reports were reviewed along with re-review by an independent radiologist to evaluate for radiologic evidence of recurrent disease.

Statistical analyses

Statistical calculations were performed using STATA software Version 12.1 (StataCorp, Texas, USA). Continuous data are summarized as mean and standard deviation. Comparison was performed using student's t-test for continuous data. Categorical variables were expressed as valid percentages and compared using Kruskal-Wallis tests assuming non-parametric distribution. Survival outcomes were explored using Cox proportional hazards model. Alpha was fixed at 0.05 for statistical significance.

Results

The demographic details of the subjects are described in Table I. CRS was performed in 71 patients (Median age 55.1, IQR 47.1 – 61.8 years), of whom FL-LTH resection was performed in 57 patients (80.3%). The most prevalent primary was appendiceal (46.5%), followed by colorectal (32.4%) and gastric (5.6%). The median PCI score at laparotomy was 13 (IQR 6-23). CC0 cytoreduction was achieved in 81.4%. The median length of stay was 10 (IQR 8 - 14) days. Grade 3-5 complications were reported in 13 (18.0%). At a mean follow up of 11.3 (± 7.3) months 61 (85.9%) were alive and under follow up. Of these, 24 were disease free (39.3%), 16 (26.2%) reported stable disease and 21 (34.4%) progressive disease.

In 38 cases, FL-LTH was performed for visible disease of which 6 were false positive. This occurred due to fibroadipose tissue that appeared to be tumor ridden. Of the 19 patients that underwent routine resections without any obvious disease, 1 (5.3%) was positive for carcinomatosis. Serial sectioning of the tissue in this patient revealed a well circumscribed nodule on gross examination that was identified as a focus of metastatic adenocarcinoma on microscopic examination.

The sensitivity and specificity of visual examination were 97.4% and 75.0%, respectively, assuming pathological examination (microscopic) as gold standard. Visual examination falsely classified 1/33 cases as free of disease (3.0% False-negative, patient had carcinoma) and 6/24 as diseased (25% False-positive patients had fibrous tissue) as described in Table II. The visual findings of the operating surgeons and pathology

findings of the resected FL-LTH specimens are described in Table III along with their primary tumor histology. False-positive resections were not associated with increased complications (0/6). Overall, FL-LTH specific complication was reported in 1 case (0.2%) in which bleeding was encountered from the left portal vein which was easily controlled with a prolene suture.

The recurrence in porta-hepatis (of n=48 with CC0 cytoreduction) was lower in the resected group (3/41, 7.3%) vs. un-resected (2/7, 28.6%), and associated with a hazard-ratio of 0.17 (95% CI 0.02 – 1.20, p-value 0.07) at a median follow-up of 11 (IQR 7.0 – 16.7) months.

Discussion

The sub-peritoneal space is invested with lymphatics and vasculature and play an important role in the intra-abdominal spread of pathology including malignancies [10]. The falciform ligament and ligamentum teres hepatis (FL-LTH) are part of the large pre-peritoneal

Table I: Baseline Characteristics and Outcomes of Patients Who Received CRS+HIPEC for Peritoneal Carcinomatosis.

| Characteristic (n=72) | Median (IQR) | Frequency n (%) |
|---|--------------------|-----------------|
| Age of cytoreductive surgery (in years) | 55.1 (47.1 – 61.8) | |
| Gender | | |
| Male | | 36 (50.7) |
| Female | | 35 (49.3) |
| Primary Tumor Diagnosis | | |
| Appendiceal | | 33 (46.5) |
| Colorectal | | 23 (32.4) |
| Gastric | | 4 (5.6) |
| Ovarian | | 3 (4.2) |
| Sarcoma | | 2 (2.8) |
| Others | | 6 (8.5) |
| Preoperative imaging | | |
| CT | | 65 (91.5) |
| PET | | 48 (67.6) |
| MRI | | 36 (50.7) |
| PCI score at laparotomy (n=55) | 13 (6-23) | |
| Completeness of cytoreduction (n=59) | | |
| CC0 | | 48 (81.4) |
| CC1 | | 9 (15.2) |
| CC2 | | 2 (3.4) |
| Length of stay (days) | 10 (8-14) | |
| Grade 3-5 Clavien- grade complications | | 13 (18.0) |
| Patients alive and under follow up | | 61 (85.9) |
| Status at last office visit (n = 60) | | |
| No disease | | 24 (39.3) |
| Stable disease | | 16 (26.2) |
| Progressive disease | | 21 (34.4) |

CRS Cytoreductive surgery, HIPEC Hyperthermic intraperitoneal chemotherapy, CT Computerized Tomography, PET Positron Emission Tomography, MRI Magnetic Resonance Imaging, CC Completeness of Cytoreduction.

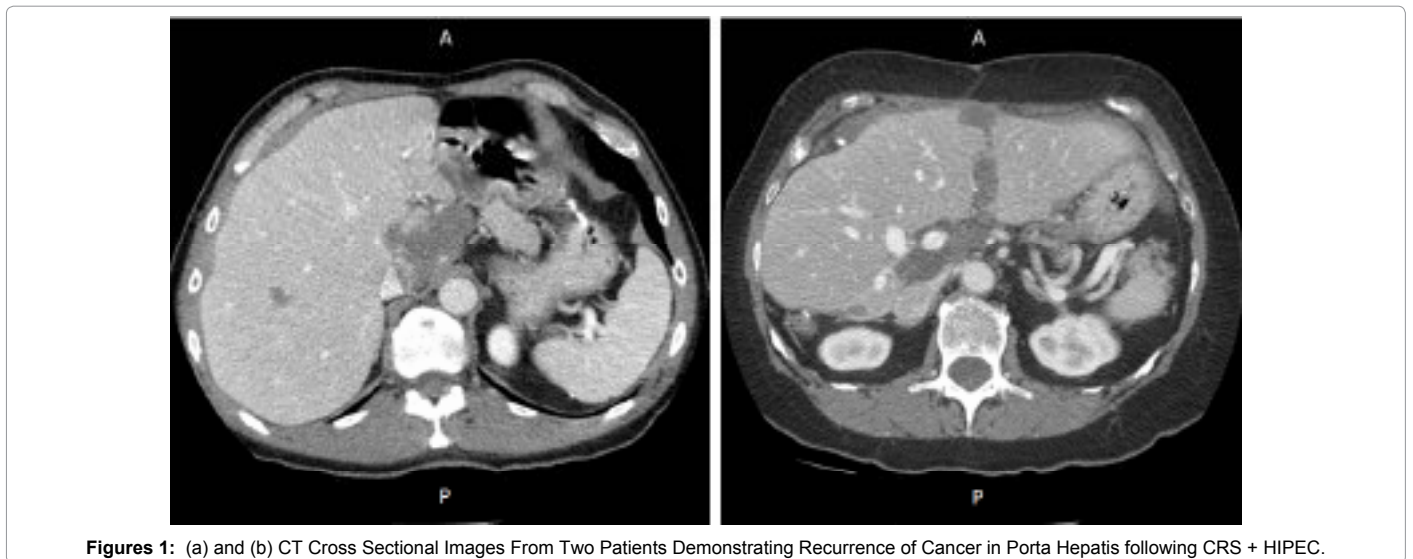
Table II: Comparison of Visual Findings of Surgeons with the Final Pathology Findings for Falciform Ligament and Ligamentum Teres Hepatis (N = 57).

| Visual Finding | Pathological Finding for Cancer | | Total |
|------------------|---------------------------------|----------|-------|
| | Positive | Negative | |
| Appears diseased | 32 | 6 | 38 |
| Not diseased | 1 | 18 | 19 |
| Total | 33 | 24 | 57 |

P-value<0.001

Table III: Comparison of the Visual Finding from Surgeon's Operative Dictation and Pathology Finding (Microscopic) for the Discordant Cases along with Primary Tumor Histology (n = 7).

| Category | Visual Finding from Surgeon's Operative Dictation | Pathology Finding (Microscopic) | Primary Tumor Histology |
|--|--|---|---|
| Visual positive for disease and pathology negative | | | |
| Case#1 | "There was disease on the patient's gallbladder, surface of the liver, on the patient's spleen, and then on both hemidiaphragms that had caked the diaphragms" | Fibro fatty tissue, negative for malignancy | Mucinous cystadenocarcinoma, low grade appendiceal primary |
| Case#2 | "This (Falciform Ligament) was covered in tumor as well" | Fibroadipose tissue, negative for malignancy | Moderately-differentiated, mucinous adenocarcinoma appendiceal primary |
| Case#3 | "The patient had disease over the falciform ligament and the ligamentum teres hepatis" | Fibrocollagenous tissue with no diagnostic abnormality | Ovarian high grade papillary serous carcinoma |
| Case#4 | "There were nodules noted by the ligamentum teres hepatis" | Negative for malignancy | Metastatic poorly-differentiated mucinous adenocarcinoma appendiceal primary with signet ring cell features |
| Case#5 | "We also noticed mucinous implants over the falciform ligament and ligamentum teres hepatis" | Fragments of mesothelial-lined fibroadipose tissue. No tumor seen | Well-differentiated mucinous appendiceal adenocarcinoma appendiceal primary |
| Case#6 | "The patient had disease over the right hemidiaphragm, falciform ligament" | Negative for malignancy | Metastatic mucinous adenocarcinoma with signet ring cell features appendiceal primary |
| Visual negative for disease and pathology Positive | | | |
| Case#7 | "LS1 in zone 1, LS0 in zone 2" | Metastatic poorly different adenocarcinoma | Diffuse poorly differentiated adenocarcinoma with signet ring cell features Appendiceal primary |



Figures 1: (a) and (b) CT Cross Sectional Images From Two Patients Demonstrating Recurrence of Cancer in Porta Hepatis following CRS + HIPEC.

space anchoring liver antero-posteriorly to the abdominal wall [10,11]. The superficial lymphatics of the liver traverse through the FL-LTH, and may potentially play a role in the peri-hepatic recurrence of cancer demonstrated in Figures 1 (a) and (b) [11]. Therefore, routine resection of this ligament is an important consideration to delay disease progression. The present study revealed trend towards decreased porta-hepatis recurrence in patients that underwent FL-LTH resection. Further, the study also demonstrated that visual examination as a basis for resection of FL-LTH result in missed disease and supports the role of a routine resection.

The necessity of routine resection can be weighed against any increased risk of complications. In our study, there was no increased risk of complications in those who underwent resections in the absence of disease (final pathology negative). One of the feared complications of dissection in this area is the damage to left portal vein and left hepatic artery (LHA) due to the proximity of liver attachment of FL-LTH [7]. Alterations in the anatomy due to adhesions from cancer and past surgery may enhance the risk of this complication. In the current sample none of the patients that underwent FL-LTH resection reported LHA damage. However, the current study maybe underpowered to detect a difference and investigation in a multi-centric setting is warranted. It is also important to note that our center is a high volume center for

CRS+HIPEC. The complication rate may be higher in a center with less experience in CRS+HIPEC.

The technique for FL-LTH resection has been described by Sugarbaker and others [7]. We have employed the use of the LigaSure to obtain a hemostatic margin of the ligament which can be done expeditiously. It is fairly safe in the setting of minimal or no disease, but can be technically challenging in patients with extensive mucinous disease in the porta hepatis. In such cases, dissection of the left portal vein to protect it is important before resection of the LTH. We also concur that opening the pont hepatic is essential to the complete clearance of disease and failure to do so, often leads to early recurrences in this area [7].

Imaging for peritoneal disease is difficult and recurrences are often occult on imaging. We have employed diffusion weighted Magnetic Resonance Imaging (MRI) technology for follow up of high risk patients but the increased duration and discomfort for patients makes it difficult to utilize for all patients. The porta hepatis is unique in its radiographic interface due to its clearly defined boundaries and lack of adjacent bowel motion which can obscure small implants. Subsequently, early recurrences can be easily detected. We believe therefore that the chance of detecting early recurrences is much higher than other sites

of peritoneal disease. Nevertheless, we recognize the limitations of imaging only assessment of peritoneal recurrence.

The additional time and cost of a FL-LTH resection is minimal and can be performed expeditiously by an experienced surgeon. This can also be done easily laparoscopically and lends itself to incorporation into the surgical algorithm for patients undergoing cytoreduction. Surprising in our study was the inconsistencies between the visual examination and the final pathology. While, this was mainly due to fibrous obliteration or mucin, it speaks to the need for better intra-operative assessment of peritoneal disease. Routine resection of FL-LTH is easy, but lends itself to another controversial subject of routine versus selective peritonectomies for patients with peritoneal disease. At present, there is no consensus for this practice although most centers employ selective peritonectomy techniques.

Conclusions

Visual examination during CRS-HIPEC may be unreliable for detecting disease at the falciform ligament, and can adversely impact on the treatment outcome if used as the basis for resection. Resection is not associated with increased complications and should be routinely performed during CRS+HIPEC.

References

1. Sugarbaker PH (2005) Peritoneal surface oncology: review of a personal experience with colorectal and appendiceal malignancy. *Tech Coloproctol* 9: 95-103.
2. Chua TC, Quinn LE, Zhao J, Morris DL (2013) Iterative cytoreductive surgery and hyperthermic intraperitoneal chemotherapy for recurrent peritoneal metastases. *J Surg Oncol* 108: 81-88.
3. Iversen LH, Rasmussen PC, Laurberg S (2013) Value of laparoscopy before cytoreductive surgery and hyperthermic intraperitoneal chemotherapy for peritoneal carcinomatosis. *The British journal of surgery* 100: 285-292.
4. Golsse N, Bakrin N, Passot G, Mohamed F, Vaudoier D, et al. (2012) Iterative procedures combining cytoreductive surgery with hyperthermic intraperitoneal chemotherapy for peritoneal recurrence: postoperative and long-term results. *J Surg Oncol* 106: 197-203.
5. Klaver YL, de Hingh IH, Boot H, Verwaal VJ (2011) Results of cytoreductive surgery and hyperthermic intraperitoneal chemotherapy after early failure of adjuvant systemic chemotherapy. *J Surg Oncol* 103: 431-434.
6. Jayakrishnan TT, Zacharias AJ, Sharma A (2014) Role of Laparoscopy in Patients with Peritoneal Metastases Considered for Cytoreductive Surgery and Hyperthermic Intraperitoneal Chemotherapy (HIPEC). In: *Medical College of Wisconsin*.
7. Sugarbaker PH (2010) Pont hepatic (hepatic bridge), an important anatomic structure in cytoreductive surgery. *J Surg Oncol* 101: 251-252.
8. Sugarbaker PH, Bijelic L (2008) The porta hepatis as a site of recurrence of mucinous appendiceal neoplasms treated by cytoreductive surgery and perioperative intraperitoneal chemotherapy. *Tumori* 94: 694-700.
9. Turaga K, Levine E, Barone R, Sticca R, Petrelli N, et al. (2014) Consensus guidelines from The American Society of Peritoneal Surface Malignancies on standardizing the delivery of hyperthermic intraperitoneal chemotherapy (HIPEC) in colorectal cancer patients in the United States. *Ann Surg Oncol* 21: 1501-1505.
10. Silverman PM (2004) The subperitoneal space: mechanisms of tumour spread in the peritoneal cavity, mesentery, and omentum. *Cancer imaging: the official publication of the International Cancer Imaging Society* 4: 25-29.
11. Gore RM, Newmark GM, Thakrar KH, Mehta UK, Berlin JW (2009) Pathways of abdominal tumour spread: the role of the subperitoneal space. *Cancer Imaging* 9: 112-120.