

3D Imaging of Joints in the Upright Weight-bearing Position using Multitom Rax

Robyn M Benz, Anna Hirschmann*

Department of Radiology and Nuclear Medicine, University of Basel Hospital, Switzerland

Description

In fall 2015 a new multifunctional X-ray machine, Multitom Rax, was launched by Siemens Healthcare (Erlangen/Germany). It is the first multifunctional X-ray unit to permit conventional x-ray imaging as well as fluoroscopy and 3D tomography. A highly specialized robotic mechanic allows to perform X-rays from any angle, facilitating imaging of immobile patients or patients that are difficult to position due to pain. This innovation also enables the system to acquire 3D tomography with high-resolution computed tomography (CT) images. Images are achieved at a frame rate of 8 images per second while the tube and detector rotate around the patient in a curved line, called trajectory. There are three trajectories, which are defined by their position and the angle of the arc covered by the unit. Ground breaking is the upright trajectory of Multitom Rax. This is feasible due to two freely and independently moving telescopic arms allowing patients to be scanned standing on both legs in a physiologic and comfortable position (Figure 1). Therefore, it is possible to image peripheral as well as central joints, such as the hip or the spine, under weight-bearing conditions. Three-dimensional imaging of joints is necessary for precise evaluation of joint alignment and pathologies. To date, upright weight-bearing CT examinations of the knee and ankle joints were feasible using extremity scanners [1-5]. The new design of Multitom Rax now allows scanning of the hips, the pelvis and the spine in an upright weight-bearing position. One potential benefit is the evaluation of stenosis of the spinal canal and neuroforamen, which can be more severe in an upright weight-bearing position as compared to the standard supine position. Beside the upright patient position, it is also possible to image in a supine position.

The first application of this 3D tomography requires careful evaluation of image quality and patient safety, especially radiation dose. In ongoing research, we found on an anthropometric phantom that spatial resolution is higher in 3D tomography as compared to conventional CT, but soft tissue contrast is momentarily limited. Therefore, we expect application to be predominantly in musculoskeletal imaging for evaluation of bones and joints. In a second study we found that image quality of the lumbar spine of cadaveric specimens is comparable to CT in normal weight and slightly overweight subjects. Currently, there are still restrictions of image quality in obese bodies (Figure 2) and radiation dose seems to be higher than in CT. We thoroughly discussed these findings with the developers and experts. Their ongoing work is improving image quality and it is to be expected to reduce patient dose by the time the 3D tomography software of the Multitom Rax will be introduced to the market.

Our experiences with application on peripheral joints as well as the trunk in patients are also promising. Detailed depiction of injured joints with inconspicuous X-ray allows advanced assessment with regard to fractures (Figure 2). Also weight-bearing studies, mainly of the spine and joints of the lower extremity, in patients with undefined pain and joint deformity yield accurate imaging without overlay. A further advantage is that the 3D images can be acquired during the same session as the X-rays and are tolerated well even by patients suffering from severe pain. The fluoroscopy component aids adjusting immobile joints to improve the images or allows joint injections such as arthrographies or infiltrations.

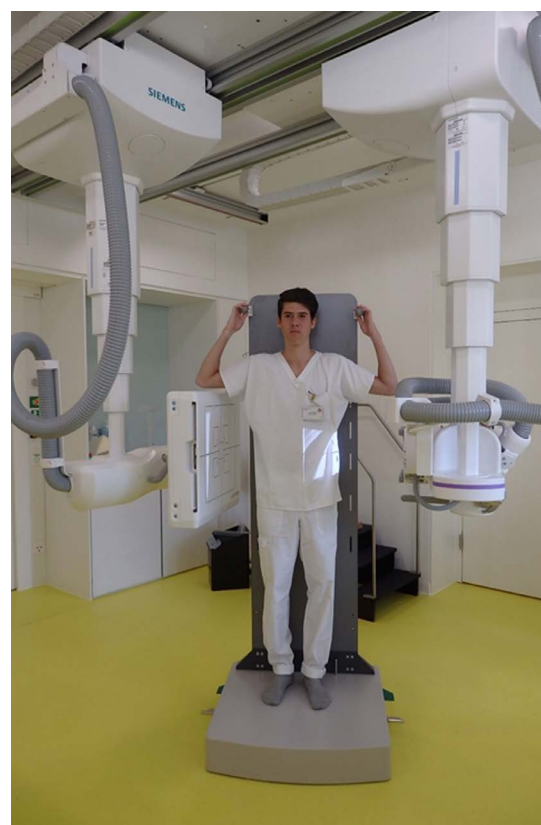


Figure 1: Multitom Rax (Siemens Healthcare) is a multifunctional X-ray machine facilitating X-rays, fluoroscopy and 3D tomography due to a robotic mechanic to which the X-ray tube and the detector are attached. Shown is the adjustment of a 3D tomography of the lumbar spine in the upright weight-bearing position. Additionally, supine 3D tomography is feasible.

Operation of the X-ray unit is simple. Reconstruction of the 3D tomography images is analogue to CT images and therefore only demands little training of radiographers.

A further advantage is the multifunctionality of the unit that allows adaption to fluctuating demands for X-rays or joint injections and therefore helps managing the occupancy rates. 3D tomography using

***Corresponding author:** Anna Hirschmann, Department of Radiology and Nuclear Medicine, University of Basel Hospital, Petersgraben 4, 4031 Basel, Switzerland, Tel: +41612652525; E-mail: anna.hirschmann@usb.ch

Received February 22, 2015; **Accepted** February 27, 2016; **Published** February 29, 2016

Citation: Benz RM, Hirschmann A (2016) 3D Imaging of Joints in the Upright Weight-bearing Position using Multitom Rax. J Trauma Treat 5: 291. doi:10.4172/2167-1222.1000291

Copyright: © 2016 Benz RM, et al. This is an open-access article distributed under the terms of the Creative Commons Attribution License, which permits unrestricted use, distribution, and reproduction in any medium, provided the original author and source are credited.

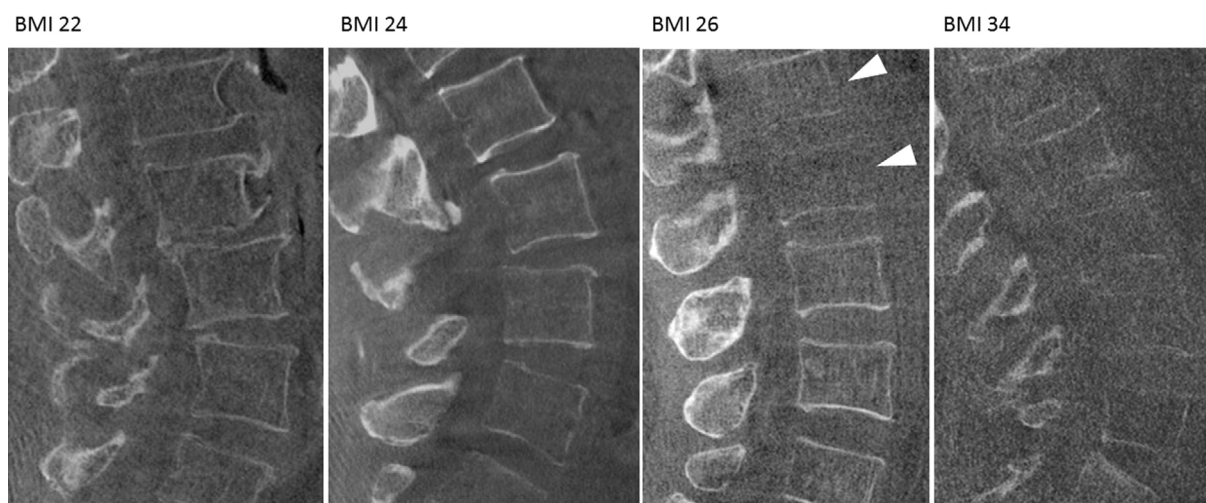


Figure 2: Comparison of image quality of the lumbar spine of cadaveric specimens in the upright weight-bearing position with different body constitutions using Multitom Rax. Excellent image quality is achievable for normal constitution, image quality is impaired with BMI higher 30 kg/m². Note the high image noise at level T12 and L1 (arrows) related to the arms of the cadaveric specimen, which could not be elevated higher.

the upright weight-bearing position facilitates and improves diagnostic evaluation of the spine and lower extremities and complements X-ray diagnostics in a trauma setting.

References

1. Tuominen EK, Kankare J, Koskinen SK, Mattila KT (2013) Weight-bearing CT imaging of the lower extremity. *AJR Am J Roentgenol* 200: 146–148.
2. Hirschmann A, Buck FM, Fucentese SF, Pfirrmann CW (2015) Upright CT of the knee: the effect of weight-bearing on joint alignment. *Eur Radiol* 25: 3398–3404.
3. Hirschmann A, Pfirrmann CW, Klammer G, Espinosa N, Buck FM (2014) Upright cone CT of the hindfoot: comparison of the non-weight-bearing with the upright weight-bearing position. *Eur Radiol* 24: 553–558.
4. Hirschmann A, Buck FM, Herschel R, Pfirrmann CWA, Fucentese SF (2015) Upright weight-bearing CT of the knee during flexion: changes of the patellofemoral and tibiofemoral articulations between 0° and 120°. *Knee Surg Sports Traumatol Arthrosc* In Press.
5. Carrino JA, Muhit AA, Zbijewski W, Thawait GK, Stayman JW et al. (2014) Dedicated Cone-Beam CT System for Extremity Imaging. *Radiology* 270: 816–824.