

“Damage Control” Esophagogastrectomy in Case of Perforated and Bleeding Gastroesophageal Cancer

Bogdan Moldovan¹, Dumitru Pocreață¹, Dan Teodorescu², Marius Coroș³, Viorica Sârbu⁴, Lucian Băilă⁵, Marcel Tanțău⁶, Dragos Grusea⁴, Florentina Pescaru⁷, Andreea Moldovan⁸ and Laura Biriș⁹

¹Surgery Unit, „St. Constantin” Private Hospital, Brașov, Romania

²Surgery Department, Brașov County Emergency Hospital, Brașov, Romania

³First Surgery Unit, Mureș Clinical County Hospital, Tg. Mureș, Romania

⁴Department of Anesthesiology and Intensive Care, Brașov County Emergency Hospital, Brașov, Romania

⁵Department of Anaesthesiology and Intensive Care, Mureș Clinical County Hospital, Tg. Mureș, Romania

⁶3rd Internal Medicine Unit, Medical Centre of Gastroenterology, Hepatology and Digestive Endoscopy, Cluj-Napoca, Romania

⁷Oncology Unit, „St. Constantin” Private Hospital, Brașov, Romania

⁸Department of Nosocomial Infection Control, „St. Constantin” Private Hospital, Brașov, Romania

⁹Regina Maria” Radiology Centre, Brașov, Romania

Abstract

Introduction: The term “damage control surgery” or “laparotomie écourtée” is not a new concept, but a recent paradigm in the surgery of abdominal trauma, when the ability to maintain homeostasis is impaired due to severe hemorrhage. It can be defined as a surgical method that prevents the trauma triad of death by hemorrhage control and the prevention of peritoneal contamination, while time is an essential factor. Damage control surgery is followed by vigorous resuscitation and definitive reconstruction. The concept of “damage - control” is less reflected in the literature related to surgical oncology. **Case Presentation:** A 45-year-old patient, BMI 35, presented to the Emergency Services of the Regional Hospital with abundant hematemesis and shock. The patient had been previously diagnosed with adenocarcinoma of the gastroesophageal junction subsequent to CT scan and endoscopic evaluation and was under the way to complete surgical - oncological balance with scheduled neoadjuvant chemotherapy due to the size and extension of the tumor. Emergency gastroscopy revealed an accumulation of blood in the stomach with ongoing massive hemorrhage while emergency CT scan revealed left hemopneumothorax and hemoperitoneum. Due to the hemorrhagic shock caused by hemodynamic collapse, the patient was performed emergency damage control esophagogastrectomy in the same block with the esophageal hiatus and liver segment 2. Thus the greater curvature of the stomach was preserved, stapled, as well as the intrathoracic esophageal stump and jejunostomy for alimentation were performed. During evolution, several interventions were performed sequentially: hemostasis by packing for hemorrhage control in the hiatal area (day 0), depacking (day 3), left pleural drainage (day 5), left cervicostomy for salivary drainage (day 8), right transthoracic esophagogastric anastomoses by using the Ivor-Lewis technique (day 63) and esophagogastric stenting for the treatment of anastomotic fistula (day 71). **Results:** Final evolution after three months of hospitalization, seven surgical interventions, more than 20 units of transfusion, is favorable. The jejunostomy tube was removed on day 95, after resuming in advance oral nutrition in parallel with enteral feeding, cervicotomy closed spontaneously. The esophageal stent was removed 6 months after placement. The pathological examination revealed a G3 poorly differentiated intestinal-type gastric adenocarcinoma (Lauren classification), which infiltrated the last 4 cm of the esophagus and 6 cm of the superior gastric pole towards the lesser curvature of the stomach (pT4N2M0). The patient underwent 6 cycles of adjuvant chemotherapy with DCF, 1 year and 6 months postoperatively becoming disease free and fully reintegrated from the social-professional point of view. **Conclusion:** The presented case is a “damage control” type model approach in an imminent life-threatening situation, which successfully implements the principles of traumatology in case of a complex oncology situation and also a multidisciplinary model of approach and collaboration between multiple hospital units for saving a young cancer patient’s life.

Keywords: Damage control; Perforated gastric cancer; Emergency esophagogastrectomy

Motto: “In life-threatening situations, prognosis improved when surgeons learned not to exaggerate with doing too much to patients.”

H. Bismuth *Damage control laparotomy*

Introduction

Back in the 90’s “damage control surgery” or “laparotomie écourtée” or “abbreviated laparotomy” was described as a life-saving technique in cases of severe abdominal traumas inspired by liver traumatology where perihepatic packing dramatically improved patient’s survival rate [1]. Later, the same methods were “borrowed” for other major non-traumatic life-threatening situations such as severe postoperative bleeding or sepsis [2,3]. References to damage control surgery in case of cancer management are extremely rare in the literature, hence the particularity of this case.

Case Presentation

In June 2012, a 45-year-old obese patient, BMI (Body Mass Index)

***Corresponding author:** Bogdan Moldovan MD, PhD, Surgery Unit, “St. Constantin” Private Hospital, Brașov Transilvania University, Brașov, Faculty of General Medicine, Str. Iuliu Maniu No 49, 500091, Brașov, Romania, Tel: +40 (0) 268 30 03 00; Fax: +40 (0) 268 30 03 29; E-mail: bogdan.moldovan@spitalulstconstantin.ro

Received March 26, 2014; **Accepted** April 11, 2014; **Published** September 20, 2014

How to cite: Moldovan B, Pocreață D, Teodorescu D, Coroș M, Sârbu V, et al. “Damage Control” Esophagogastrectomy in Case of Perforated and Bleeding Gastroesophageal Cancer. Journal of Surgery [Jurnalul de chirurgie] 2014; 10(2): 173-178 DOI: [10.7438/1584-9341-10-2-14](https://doi.org/10.7438/1584-9341-10-2-14)

Copyright: © 2014 Moldovan B, et al. This is an open-access article distributed under the terms of the Creative Commons Attribution License, which permits unrestricted use, distribution, and reproduction in any medium, provided the original author and source are credited.

of 35 kg/m², presented at the Cardiology Department complaining of retrosternal pain, weight loss, fatigue and anorexia. The results of the cardiology investigations were within normal limits, exams continued with native abdominal CT, which revealed an important thickening of the gastric wall at the level of the upper pole, lesser curvature and terminal esophagus (Figure 1).

The primary gastroscopy showed a semi-circumferential lesion in the lower esophagus, the examination of the stomach could not be completed due to lack of cooperation. The patient was diagnosed with inferior esophageal cancer without retroversion examination. Due to mismatches in the CT-endoscopy results, the CT-scan was repeated with oral and i.v. contrast, which confirmed the presence of a massive gastroesophageal tumor that dilated and invaded the diaphragmatic hiatus and had no cleavage plane with the juxta-hiatal left hepatic lobe. The second gastroscopy highlighted the gastric tumor too and a biopsy sample was also prelevated.

Given the size and local-regional extension of the tumor, the patient's age and very good biological characteristics, the surgical oncology colloquium decided that the patient should be treated by neoadjuvant chemotherapy followed by radical surgery.

The proposed strategy could not be followed due to a complication that suddenly occurred at home. The patient was brought to the emergency room of the Regional Emergency Hospital with massive hematemesis and shock. An intensive care therapy was started concomitant with several exams. The upper gastrointestinal endoscopy revealed a large amount of fresh blood in the esophagus, the stomach was filled with fresh blood and clots which prevented the examination of the lining. This case proved to be beyond endoscopic therapeutic resources. The thoraco-abdominal CT scan (Figure 1) showed: left hemothorax of 13 cm in diameter, mediastinum shifted to the right, esophageal dilation in the region of the aortic arch with anfractuous contour and air around the cardia region, (possible perforation site) and pneumoperitoneum. Laboratory results on admission: Hb 8.6 g/dL, Htc 27.9%, platelets 416 000/mm³ rapidly degrading to 5.5 g/dL Hb and 15% Htc, Ph 7.097, base excess -11.8 mmol/L indicating progressive hemodynamic deterioration. Emergency surgery was decided immediately for hemostatic reasons; the proposed strategy was damage control esophagogastrectomy.

Day 0, 18:25 hour

We performed bisubcostal laparotomy incision, while the patient was agonizing before intubation, his blood pressure was 70/55 mmHg and pulse rate 153/min. We positioned the Thompson retractor and identified a massive tension hemoperitoneum ("moribond à gros ventre") of over 2000 mL, which was immediately removed. Subsequently we detected an perforated gastric tumor, with a niche of more than 3 cm, while the stomach and terminal esophagus were a mass of blood clots. We performed a rapid evacuation of the stomach content and temporary hemostasis with intraluminal manual compression. After hemodynamic stabilization, we used intraluminal tamponade. After ensuring the eso-gastric junction from exposure, the intervention continued with the skeletonization of the upper gastric pole by using a 10 mm termofusion vessel sealing device, the resection of the diaphragmatic hiatus adherent to the tumor and of a portion of the hepatic segment II adherent to the tumor. The transhiatal preparation of the intrathoracic esophagus continued which was then stapled transversally by using a 60 mm stapler at about 3 cm cranially from the macroscopic edge of the tumor. Subsequently a gastric upper polar resection was performed, preserving most of the greater curvature and cutting more of the lesser curvature at the same time doing locoregional lymph node dissection. The stomach was completely closed by using 3 60 mm staplers. In the final stage of the intervention we performed Albert feeding jejunostomy with double subhepatic and juxta-hiatal drainage. A naso-esophageal tube was also positioned at the level of the esophageal stapled stump. The intervention lasted for 90 minutes and the parameters after transfusion on exit from the operating theatre were: blood pressure at 111/70 mmHg, pulse rate at 135/min, Hb at 6 g/dL, Htc at 15.8%, pH at 7.24, base excess -6.5 mmol/L.

Day 0, 00:45 hour

Reoperation was necessary because of hemorrhage (1500 mL) through the two drains. Diffuse bleeding ("biological" not "surgical" bleeding) was identified in the area of the diaphragmatic hiatus, followed by the evacuation of the hemoperitoneum, lavage with warm fluids and local packing, laparorrhaphy just on the anterior rectus sheath to prevent compartment syndrome. Postoperative course was favorable; the total amount of transfusions in the first 24 hours was of 15 units of packed red blood cells and 14 units of fresh plasma.

The pathological examination of the sample collected during esophagogastrectomy revealed a poorly differentiated adenocarcinoma

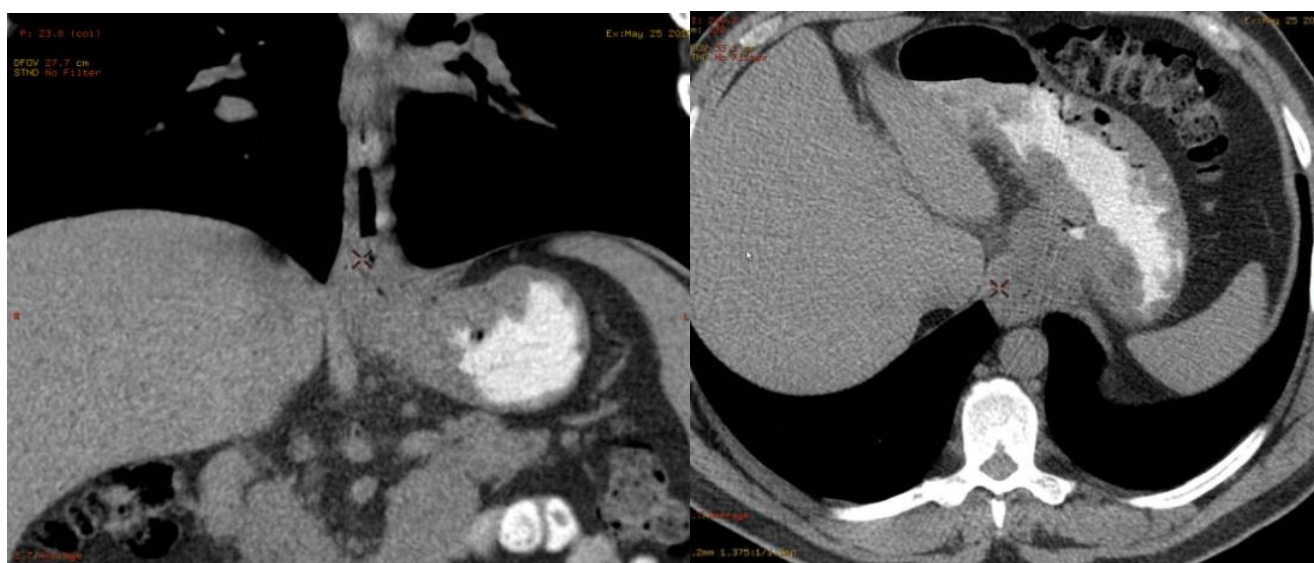


Figure 1: Initial CT showing a stenosing esophagogastric bulky mass.

(G₃) of intestinal type (Lauren classification) that invaded all layers of the cardia, presenting a central perforation, the invasion of the hiatal muscle and adjacent hepatic parenchyma. The tumor was 4 cm long at the level of the terminal esophagus and its overall dimensions were 12 x 7 cm. There were 22 lymph nodes examined in total, out of which three presented metastatic adenocarcinoma with infiltration beyond the capsule. There were no lymphatic emboli, only the signs of perivascular and perineural invasion; the stage was pT4N2Mx.

Day 3

Reintervention was performed for depacking, lavage and drainage, while no active sources were observed. Unfortunately the naso-esophageal tube had been removed accidentally during postoperative transfer, which had negative consequences afterward.

Day 5

The patient presented fever, dyspnea, inflammatory syndrome, the chest X-ray showed left-sided pleural effusion. Left pleural drainage evacuated about 700 mL hemato-purulent fluid. In the absence of the naso-esophageal tube, we suspected the presence of a left esophageal-pleural stump fistula, which was confirmed on day 6 with a hydro soluble contrast passage.

Day 7

The intervention for cervicostomy of salivary drainage was relatively difficult due to obesity and the depth of the intervention. We used a silicone drainage rod. The esophagus subjacent to the silicone rod was ligated with two relatively loose PDS[®] sutures, so that they could not have produced ischemia and sectioning of the esophagus. The opened esophagus, superior to the stent, was attached to the skin with crown PDS[®] 3-0 sutures. The patient experienced postoperative recurrent palsy syndrome associated with dysphonia and tirage and dyspnea with spontaneously favorable evolution in about 4 weeks. The pleural drain was suppressed 14 days after cervicotomy, when the drainage was stopped.

Preparing thoracic intervention

This stage consisted of combined parenteral and enteral nutrition over a period of two months. During this time the patient was hospitalized in the ICU for over 50 days, and then transferred to the general ward 7 days preoperatively.

The list of medical problems prior to reconstructive surgery comprised the followings:

1. Despite enteral and parenteral nutrition the patient had a poor nutritional status. Because of multiple septic foci the patient had lost about 15 kg and proteinemia oscillated between 5.2 and maximum 5.7 g/dL. A persistent diarrhea syndrome secondary to enteral feeding created difficulties in managing the enteral route.

2. Foci of infection: initially left pleural effusion by esophago-pleural fistula with *Enterococcus faecalis* revealed in culture, then infection of the operative abdominal wound due to repeated interventions and episodes of septicemia caused by immunosuppression (initial oncological disease associated with prolonged hospitalization and series of abdominal surgery and transfusions), isolation of *Klebsiella pneumoniae* ESBL + followed by a central venous catheter sepsis with positive cultures of multi-resistant *Pseudomonas aeruginosa*, *Acinetobacter* spp. and methicillin-resistant *Staphylococcus aureus* (MRSA) sampled from the site of the catheter. The following germs were sampled at the level of the cutaneous insertion of the jejunostomy: non-ESBL producing *Escherichia coli*, multi-resistant *Serratia rubidaea*, *Pseudomonas* spp and *Candida krusei* (natural resistance to fluconazole, sensitive to amphotericin B, itraconazole). These infectious episodes required prolonged antibiotic therapy, adapted according to the antibiogram and

the high level resistance of isolated germs to basic antibiotics (ceftriaxone + metronidazole, augmentin, vancomycin, imipenem + linezolid, fluconazole, subsequently itraconazole then finally trimethoprim-sulfamethoxazole). Regarding all these infectious problems the evolution of the patient was favorable. There were no signs of clinical or biological parameters suggesting infection before reconstructive surgery.

Timeline of reconstructive surgery

24 hours before surgery we carried out a cervical exploration. We removed the wires used for esophageal ligation and established the integrity of the cervical esophagus.

Abdominal assessment consisted of exhaustive adhesiolysis, complete discharge of the gastric tube, total duodeno-pancreatic mobilisation, extramucosal pyloromyotomy by re-laparotomy. Permeability was manually regenerated in the completely closed esophageal hiatus by performing combined thoracic and abdominal intervention.

The next step of the intervention on the time line was a thoracic intervention (Ivor-Lewis) consisted of right inferior posterolateral thoracotomy in the seventh intercostal space, the identification and isolation of the inferior esophagus below the azygos vein, the resection of an oesophageal sample of about 3 cm (the resection margins were free of tumor according to the initial histopathological results), the insertion of a gastric tube through a transhiatal intrathoracic approach and biplane esogastric termino-terminal anastomosis with running suture (3-0 Prolene[®] externally, PDS[®] 3-0 internally). Passive right chest drainage and abdominal drainage were applied. The ascending stomach was anchored to the prevertebral fascia in an unstressed position. The consistency of the gastric tube was carton-like, without flexibility and length in comparison to the initial operation, this issue being one of the disadvantages of a two-step approach.

Immediate postoperative evolution was favorable, the patient was extubated in the evening of the surgery. Due to low-dose parenteral and enteral protein intake proteinemia decreased to 4.8 mg/dL. On day 7 postoperatively there was a quantitative increase of the right pleural drainage and the oral administration of methylene blue revealed the extravasation of dye through chest drainage without altering the patient's general condition. So we had two options: 1) to re-operate the patient for the removal of the anastomosis and return to the initial status or, 2) to manage the patient conservatively by placing an esophageal endoprosthesis. As the general condition was stable, we opted for the second alternative; so the patient was referred to a gastroenterological unit and stenting of the anastomosis using a 10 cm waterproof stent was performed (Figure 2).

Post-procedural follow-up was immediately favorable thus oral feeding with liquids was reintroduced in about 48 hours, the pleural drain was removed on day 14 and feeding jejunostomy at four weeks after surgery.

Patient received adjuvant chemotherapy, 6 cycles of DCF (docetaxel 75 mg/m² day 1, Cisplatin 75 mg/m² day 1, 5-Fluorouracil 750 mg/m²/day day 1- 4 continuously) and underwent repeated imagistic follow-up (CT, MRI) (Figure 3). The patient did not show any clinic, imagistic and biologic signs of relapse 18 months after to surgery. The stent was suppressed 6 months after installation with no particular difficulties and cervicotomy closed spontaneously (Figure 4). The patient is presently fully reintegrated from the social-professional point of view.

Discussions

"Damage Control Surgery" addresses dramatic cases with severe active bleeding and hemodynamic instability in cases when death is imminent and is defined as a short-term intervention limited to lesion control. It comprises a series of physio-pathogenic aspects: heavy bleeding, massive transfusion, hypothermia and consumption coagu-

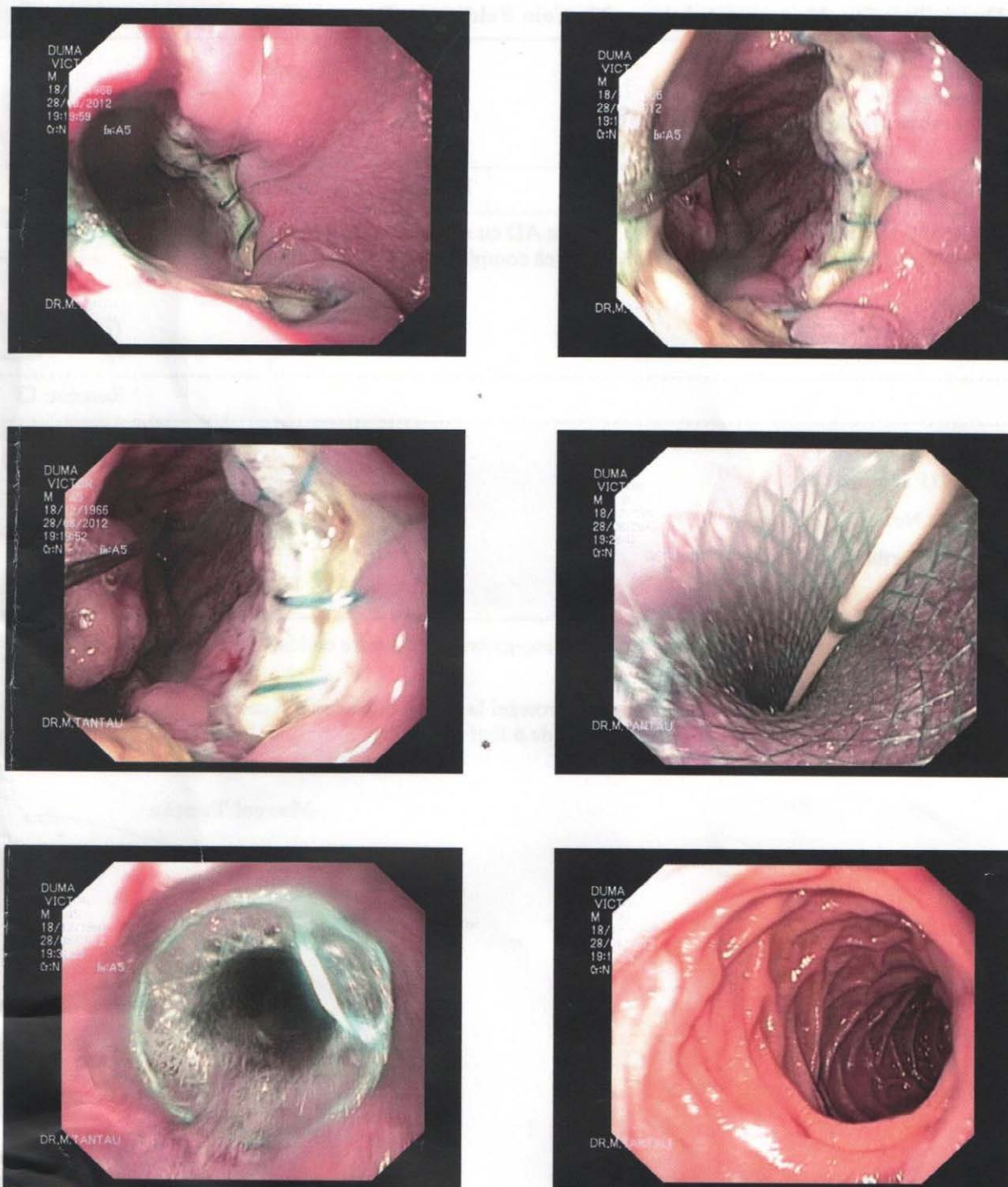


Figure 2: Endoscopic aspect of the minimal anterior anastomotic dehiscence. Mounting the stent.

lopathy responsible for the so-called “biological hemorrhage” which is not “surgical hemorrhage” [4]. There are many severity and risk factors with prognostic values in relation to coagulopathy, all being positive in this case: hypotension below 70 mmHg, active bleeding requiring minimum 2 units/ h, massive transfusion of more than 5 units, hypothermia below 34°C and acidosis with a pH value below 7.25. [4-6]

The main goal of the intervention was: to achieve rapid homeostasis by removing the damaged body part and the secondary purpose was to avoid the contamination of the peritoneal cavity by stapling the

digestive lumens or external drainage through the stomas without the restoration of digestive continuity. This was followed by vigorous resuscitation, hypothermia, acidosis and coagulation disorders had to be controlled and only then reconstructive surgery performed.

In the literature the term damage control is scarcely met for non-traumatic situations, in the surgery of colic diverticular perforation or the surgery of the pancreas and in cases of re-interventions for hemorrhage or sepsis following the Whipple procedure [2,3].

Spontaneous rupture of gastric tumors with hemoperitoneum and

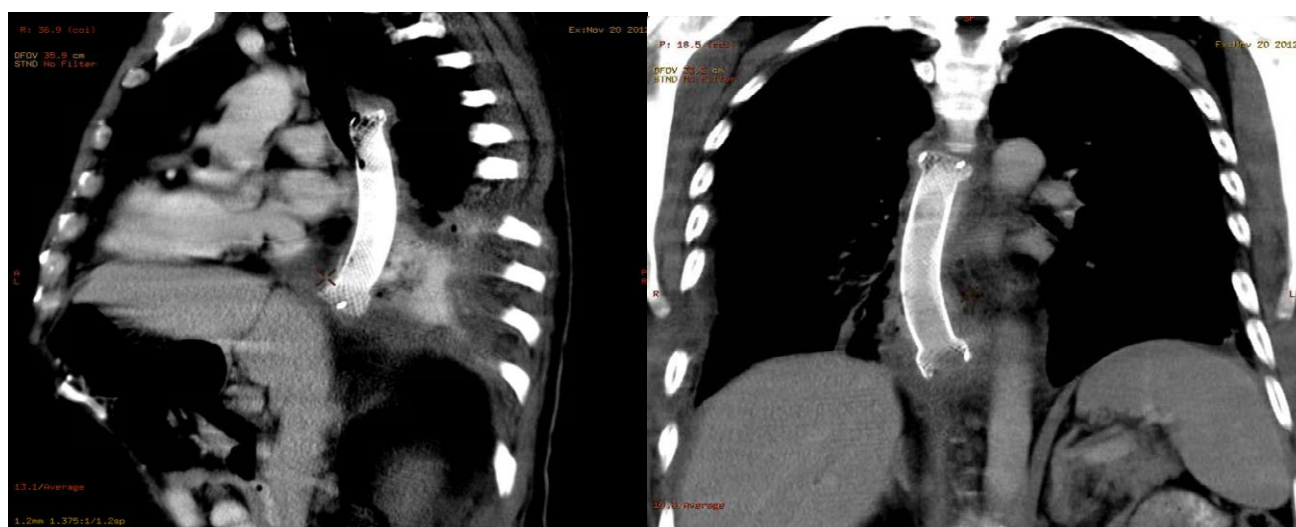


Figure 3: CT images 3 months after surgery; stent in position.

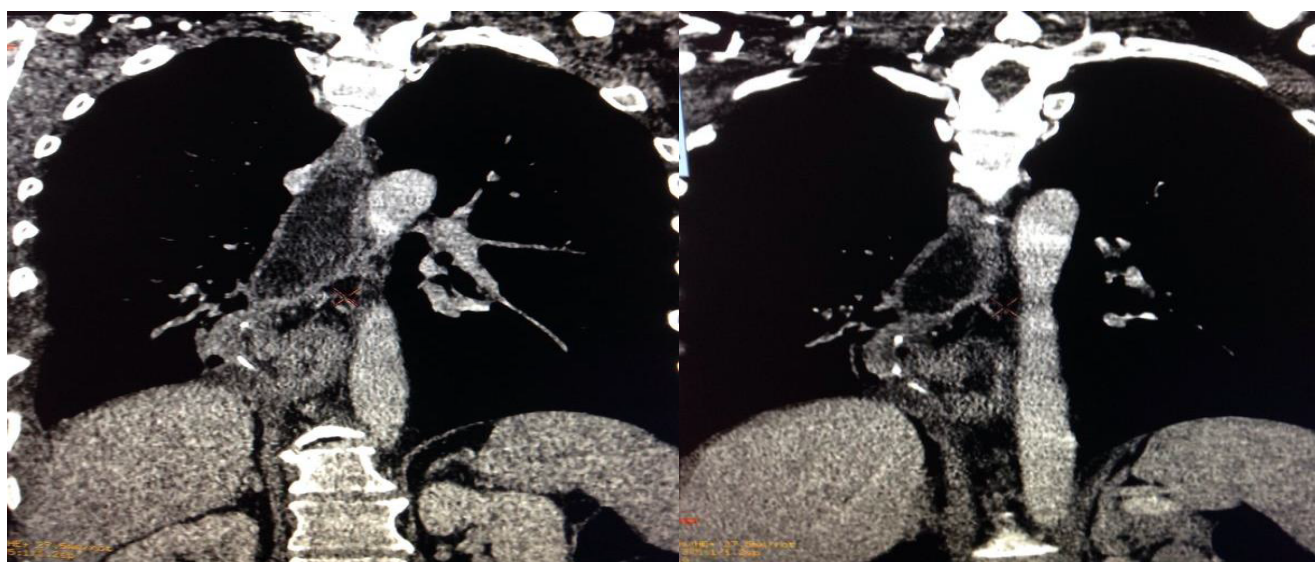


Figure 4: Chest CT scan: esogastric anastomosis after the stent removal; there are no signs of recurrence 18 months postoperatively.

gastrointestinal bleeding is a very rare and very severe clinical entity, case in which surgery is the only therapeutic solution. In our case, the final outcome, the survival of the patient and R_0 character of the surgical resection performed under the condition of an imminent catastrophe are arguments for the rightness of the attitude we opted for. Because the patient was young with preserved biological resources despite the advanced character of the disease, our therapeutic goals were the following: 1) to save the patient's life by achieving homeostasis, than 2) to restore digestive continuity and presently 3) to obtain a disease-free life as long as possible.

We would like to emphasize the importance of a multidisciplinary team: surgeon, anesthesiologist-reanimator, radiologist, gastroenterologist, infectious disease specialist, especially for solving non-surgical postoperative complications, which in our case was the stenting of the esogastric anastomosis, this way avoiding the surgical removal of the anastomosis and return to the initial situation, which significantly shortened recovery time in the patient.

Conclusions

This case is an example of “damage control” adopted in surgical

oncology in case of an imminent life-threatening situation. The joined effort of four hospitals in three counties, which meant 7 interventions under general anesthesia, three months in the hospital, 60 days of intensive care, saved the patient's life.

Acknowledgement

The principal author especially thanks to all the staff of: Department of Anesthesiology and Intensive Care, Braşov Clinical County Hospital, Department of Anaesthesiology and Intensive Care, Braşov Clinical County Emergency Hospital, Department of Anaesthesiology and Intensive Care, Târgu Mureş Clinical County Hospital, Medical Centre of Gastroenterology, Hepatology and Digestive Endoscopy, Cluj-Napoca, the team of instrument nurses working at the “St. Constantin” Private Hospital, Braşov, Romania

Conflict of Interests

Authors have no conflict of interests to disclose.

References

1. Kluger Y, Soffer D, Klausner JM (1996) [Packing and abbreviated laparotomy in the injured—a life-saving procedure]. *Harefuah* 130: 366-370, 438.
2. Kafka-Ritsch R, Birkfellner F, Perathoner A, Raab H, Nehoda H, et al. (2012) Damage control surgery with abdominal vacuum and delayed bowel recon-

- struction in patients with perforated diverticulitis Hinchey III/IV. *J Gastrointest Surg* 16: 1915-1922.
3. Morgan K, Mansker D, Adams DB (2010) Not just for trauma patients: damage control laparotomy in pancreatic surgery. *J Gastrointest Surg* 14: 768-772.
 4. Arvieux C, Letoublon C. Laparotomie ecourtee pour traitement des traumatismes abdominaux severes: principes de technique et tactique chirurgicales. *Encyclopedie Médico-Chirurgicale, Techniques chirurgicales, Appareil digestif*. Paris: Elsevier-Masson; 2005. 40-095.
 5. Burch JM, Ortiz VB, Richardson RJ, Martin RR, Mattox KL, et al. (1992) Abbreviated laparotomy and planned reoperation for critically injured patients. *Ann Surg* 215: 476-483.
 6. Cosgriff N, Moore EE, Sauaia A, Burch JM. Predicting life threatening coagulopathy in the massively transfused trauma patients: hypothermia and acidosis revisited. *Trauma*. 1997; 42: 857-862.
 7. Sharp KW, Locicero RJ (1992) Abdominal packing for surgically uncontrollable hemorrhage. *Ann Surg* 215: 467-474.